

High-flow priapism – the successful direct excision of arterio-lacunar fistula

Artur Gibas¹, Marcin Matuszewski¹, Agnieszka Bianek-Bodzak², Jerzy Jankau³, Kazimierz Krajka¹

¹Department of Urology, Medical University in Gdańsk, Poland

²Department of Radiology, Medical University in Gdańsk, Poland

³Department of Plastic Surgery, Medical University in Gdańsk, Poland

KEY WORDS

penis ▶ erection ▶ priapism ▶ high-flow priapism

ABSTRACT

High-flow priapism is a relatively rare pathology. Thus, there are not many large studies evaluating its management. The article describes the case of a patient with high-flow priapism caused by an arterio-lacunar fistula resulting from a perineal trauma affecting the base of the left cavernous body. After unsuccessful selective embolization open direct excision of the vascular malformation was performed. The localization of the lesion was enabled by clinical examination and by Doppler ultrasound. The treatment was successful and erectile function fully recovered after one month. This simple method may be of value when modern minimally invasive techniques appear to be ineffective.

CASE PRESENTATION

An 18 year old male was referred to the hospital two weeks after blunt perineal trauma during skateboard evolutions. On admission he was complaining of partial almost painless erection that has been lasting since the fourth day after the accident.

Physical examination revealed partial erection with no signs of tissue hypoxia and small induration at the base of the left cavernous body exactly in the site of the trauma pointed by the patient (Fig. 1). No other pathologies were detected.

Routine aspiration blood gasometry was performed showing high oxygen saturation proving the arterial cause of priapism.

In a colour Doppler ultrasound the lump in the left cavernous body



Fig. 1. Partial almost painless erection with small induration at the base of the left cavernous body.

was visible as a hypoechoic lesion 5 mm in size with arterial filling and maximal velocity of 45 cm/s. Thus, the diagnosis of arterio-lacunar fistula was established (Fig. 2). Then he was followed up for four weeks as spontaneous resolution was expected.

However, the patient and his parents continued to express their growing anxiety about his condition so he was referred to invasive radiology unit for arteriography with selective embolization of the fistula. During arteriography with contrast the ramifications of iliac and femoral arteries including internal pudenda artery were visualized, but no clear malformations were detected. So the embolization was not performed (Fig. 3).

Because of persistent priapism and probable localisation of the fistula showed by Doppler examination, decision of open operation with direct excision of the fistula was made.

In spinal anaesthesia and lithotomic position longitudinal medial incision was used to reach the left cavernous body. The lump corresponding to the Doppler picture was felt and the tunica albuginea was incised over it. The lesion was found and carefully excised. In order to minimize the trauma to erectile tissue no coagulation was used and all bleeders were secured with sutures. After excision it looked as small fibrous lacunar lump (Fig. 4).

The wound was closed in layers and suction drain was left in for two days. Compressive dressing was applied for 4 days.

The only postoperative complication was a small subcutaneous hematoma of the scrotum.

In the first day after the operation the erection subsided. Doppler examination performed three day after did not show the previously seen lesion. The effect was estimated as good. The patient was discharged after complete resolution of the hematoma on the 8th day post-op.

On further follow-up he reported full recovery of his erectile function in one month after the procedure.

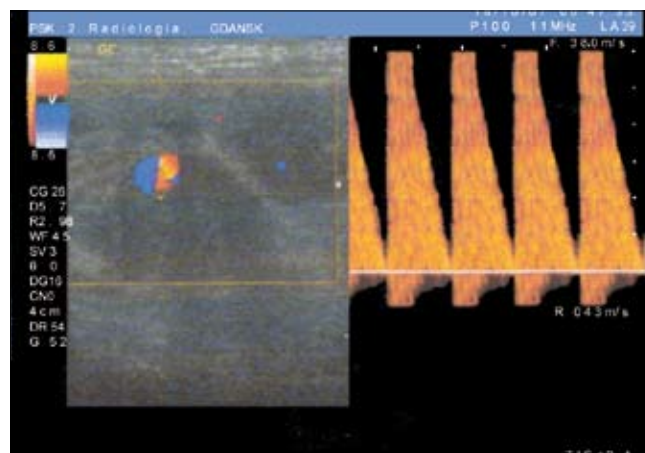


Fig. 2. Arterio-lacunar fistula with high flow visible in color Doppler study.

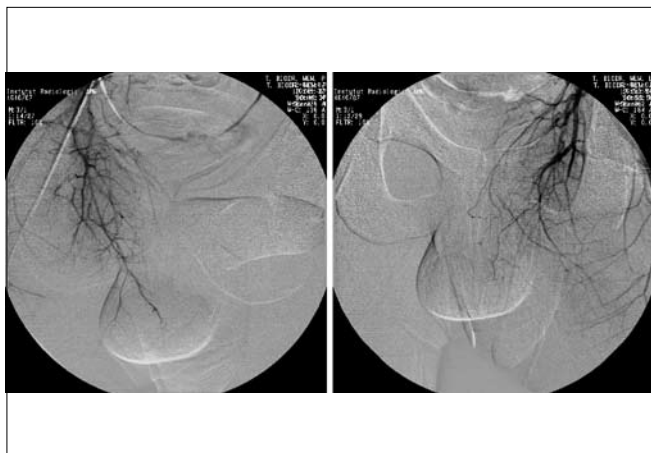


Fig. 3. Arteriography surprisingly not showing any sign of the fistula.

DISCUSSION

Priapism is a pathologic erection lasting more than 4 hours, not dependent on sexual arousal, that is not passing after the orgasm and ejaculation.

Two forms of priapism are described: high-flow and low-flow [1, 2, 3].

High-flow priapism is usually caused by trauma resulting in the formation of an arterio-lacunar fistula [2, 3, 4]. In the majority of cases it is not painful due to a continuous inflow of blood preventing hypoxia. Conservative management is usually recommended as the fistula most often closes itself and some cases of full spontaneous recovery after as long as three years were described. However, there are also reports stating that long lasting high-flow may lead to the injury of erectile tissue and consequently to erectile dysfunction. Nevertheless, prolonged erection in young patient always leads to his considerable anxiety, so most urologists decide to undertake some forms of treatment after few weeks of persistent high-flow priapism.

On admission the management should start with careful history and physical examination. The penile blood gasometry can establish the diagnosis. The Doppler test should also be performed as it is very simple and non-invasive and may easily localize the reason of priapism. Then, depending on the patient tolerance, the wait and see approach should be undertaken. But if it fails, additional active treatment is needed. There are reports demonstrating that methylene blue injection may be effective as the blood flow into the cavernous body may be an additional stimulus for nitric oxide production. Otherwise the recommended treatment is arteriography combined with selective embolization of the internal pudendal artery [2, 3, 5, 6, 7, 8]. It is potentially invasive procedure and to limit the danger of permanent erectile dysfunction absorbable material should be utilized. The results are fairly good reaching 78% of success with complication, namely loss of erection, not exceeding 5%. But it must be done by experienced radiologists and only when absolute certainty of the position of the fistula is granted [2, 3, 9, 10]. After unsuccessful or impossible (as in presented case) embolization the choice of methods is very limited, and this is confirmed by the literature on the subject. One of available options is open surgical closure of the branches of internal pudendal arteries going into cavernous body, as proposed by Ricciardi.

In the presented case it was not possible to use embolization, but we were able to localize the site of the fistula by Doppler. Thus we were able to precisely excise the fistula. We think that careful preparation can limit the injury of cavernous tissue and that reaching the injured vessels more

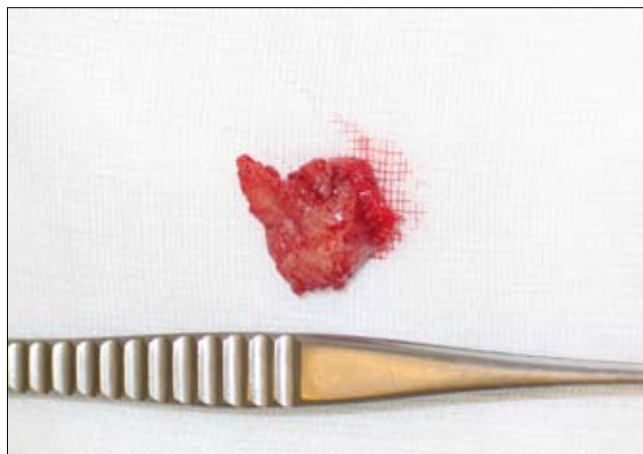


Fig. 4. The fibrous lacunar lump.

distally than entrance of internal pudendal artery into the cavernous body may create smaller risk of permanent blood supply impairment.

CONCLUSION

In our opinion in cases with high-flow priapism after failed conservative treatment the trail of embolization should be recommended. But if it fails it is reasonable to consider open excision of the fistula, as often Doppler and physical examination can precisely localize the lesion. The treatment may solve the problem instantly with a minimal risk to the erectile function.

REFERENCES

1. Lue TF: *Physiology of penile erection and pathophysiology of erectile dysfunction and priapism*. In: Walsh PC, Retik AB, Vaughn ED, Wein AJ, eds. *Campbell's Urology*. 7th ed. Philadelphia: Saunders, 1998; 1157-1179
2. Lomas CM, Jarow JP: *Risk factors for papaverine-induced priapism*. *J Urol* 1992; 147; 1280-1281.
3. Steers WD, Selby JB: *Use of methylene blue and selective embolization of the pudenda artery for high flow priapism refractory to medical and surgical treatments*. *J Urol* 1991; 146; 1361-1363.
4. Hakim LS, Kulaksizoglu II, Mulligan R et al: *Evolving concepts in the diagnosis and treatment of arterial high flow priapism*. *J Urol* 1996; 155; 541-548.
5. Neubauer S, Derakhshani P, Krug B, Lackner K et al: *Posttraumatic high-flow priapism in a 10-year-old boy: Superselective embolization of the arterio-venous fistula*. *Eur Urol* 1998; 33; 337-339.
6. Spycher MA, Hauri D: *The ultrastructure of the erectile tissue in priapism*. *J Urol* 1986; 135; 142-144.
7. Ricciardi R, Bhatt GM, Cynamon J et al: *Delayed high-flow priapism: pathophysiology and management*. *J Urol* 1993; 149; 119-121.
8. Gudichet F, Fournier D, Jichlinski P, Meyrat B: *Traumatic priapism in a child: Evaluation with colour flow Doppler sonography*. *J Urol* 1979; 148; 380-382.
9. Crummy AB, Ishizuka J, Madsen PO: *Posttraumatic priapism: Successful treatment with autologous clot embolization*. *AJR* 1979; 133; 329-331.

Correspondence

Artur Gibas
Klinika Urologii AM
ul. Kliniczna 1a
80-402 Gdańsk, Poland
phone: +48 58 34 93 823
delins@amg.gda.pl