

Laparoscopic radical cystectomy with prostate capsule sparing. Initial experience

Juan Gómez Rivas¹, Sergio Alonso y Gregorio¹, Ángel Tabernero Gómez¹, Mario Alvarez-Maestro¹, Jesús Díez Sebastián², Jesús Cisneros Ledo¹

¹Department of Urology, Hospital Universitario La Paz, Madrid, Spain

²Department of Biostatistics, Hospital Universitario La Paz, Madrid, Spain

Citation: Gómez Rivas J, Alonso y Gregorio S, Tabernero Gómez Á, Alvarez-Maestro M, Díez Sebastián J, Cisneros Ledo J. Laparoscopic radical cystectomy with prostate capsule sparing. Initial experience. Cent European J Urol. 2016; 69: 25-31

Article history

Submitted: Oct. 25, 2015
Accepted: Dec. 12, 2015
Published online: Jan. 18, 2016

Corresponding author

Juan Gómez Rivas
Hospital Universitario La Paz
261 Paseo La Castellana
28046 Madrid, Spain
phone: +34 661 190 028
juangomezr@gmail.com

Introduction In 2008, our department introduced a modified technique of laparoscopic radical cystectomy in which the prostatic capsule is spared in selected patients with bladder cancer. The different series published are mostly using the standard open procedure. The aim of this study is to describe this technique using the laparoscopic approach and present our preliminary results.

Material and methods This study includes 20 patients selected by clinical analysis and imaging criteria operated using laparoscopic radical cystectomy with prostate capsule sparing at our department in the period between 2008 and 2012.

Results Patient mean age was 58 years. Mean operative time was 390 minutes. Median follow-up was 36 months. No patient had bladder cancer recurrence. Only one patient died of disease progression, as the pathological findings was a pT3 pN1 Mx. Mean PSA before surgery: 1.3 ng/ml (0.3–2), mean PSA after surgery 1.0 ng/ml (0.08–1.7). No patients had prostate cancer recurrence. Satisfactory daytime and night-time continence was achieved. 90% of patients have sexual function preserved.

Conclusions Prostate-sparing radical cystectomy remains one of the most controversial topics in urology today. The laparoscopic approach could be an alternative to conventional radical cystoprostatectomy in well selected patients, done in experienced institutions in order to find better functional results, with a low disease progression and recurrence rate.

Key Words: laparoscopic <> cystectomy <> prostate capsule sparing

INTRODUCTION

The standard technical procedure for radical cystectomy includes the “en bloc” removal of the bladder, prostate, and seminal vesicles. Concerns about functional outcomes, such as continence and potency, play a role in decision making for many clinicians and patients, especially younger males with high-grade non-muscle-invasive disease [1].

While the quality of life associated with specific treatments is an important outcome measure, the primary endpoint for cancer treatment is, and must, remain the treatment efficacy. Several recent clinical series have described modifications to the

classic radical cystectomy, developing in the improvement of postoperative continence and potency rates [2, 3, 4]. All these series attempt to minimize dissection near the urinary sphincter and neurovascular bundles during cystectomy through partial or complete sparing of the prostate, seminal vesicles, and vasa deferentia. Functional results from these series are impressive, and may serve to improve the choice of early cystectomy in younger men. Nonetheless, valid concerns may be raised regarding the overall oncologic efficacy of prostate-sparing cystectomy and the potential impact of occult prostatic malignancy in overall recurrence and survival rates.

Laparoscopic radical cystectomy has been performed in our department since 2005 [5]. In 2008, we introduced a modified technique of laparoscopic radical cystectomy in which the prostatic capsule is spared in selected patients with bladder cancer [6]. The different series published mostly use the standard open procedure. The aim of our study is to describe this technique using the laparoscopic approach and present our results.

MATERIAL AND METHODS

This study includes 20 patients who underwent laparoscopic radical cystectomy with prostate capsule sparing in our department in the period between 2008 and 2012. The principles of the Helsinki dec-

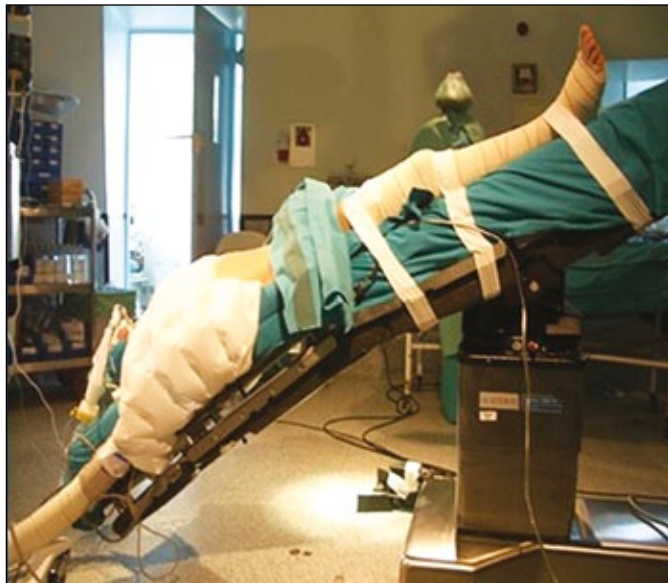

Figure 1. Trendelenburg position for laparoscopic radical cystectomy.

laration were followed and all human subjects provided written informed consent with guarantees of confidentiality.

Patients selection

All patients included referred good sexual function prior to surgery defined by having erections with successful intercourse with sexual stimulation. They had either pathologically confirmed invasive bladder cancer (clinically T2N0Mx/0), or nonmuscle-invasive bladder cancer recurrent after BCG. A complete physical examination, complete blood analysis, and computerized tomography (CT) was done. All patients had a normal digital rectal examination and prostate specific antigen (PSA) less than 4 ng/ml. Patients with >T2 / N+ bladder cancer (clinically or in CT), carcinoma *in situ*, tumors next to the bladder neck, bad prognosis pattern (for example epidermoid carcinoma), palpable nodule(s) in the prostate, and/or high PSA (>4 ng/ml) were excluded.

Surgical technique

Like any laparoscopic pelvic surgery, the patient is placed in forced Trendelenburg position (Figure 1). After the development of pneumoperitoneum, four ports are placed, two ten mm and two five mm. The peritoneum is incised at the iliac crossing level, and we continue the incision over the external iliac artery to the internal inguinal ring and caudally to the Douglas pouch. The vas deferentia are consecutively identified, and the superior bladder arteries and both ureters are dissected. Both vas deferentia are released, and, at the opening of the Douglas pouch, the front and top face of both seminal vesicles are released. After clipping and section of the superior bladder arteries and both ureters, the bladder

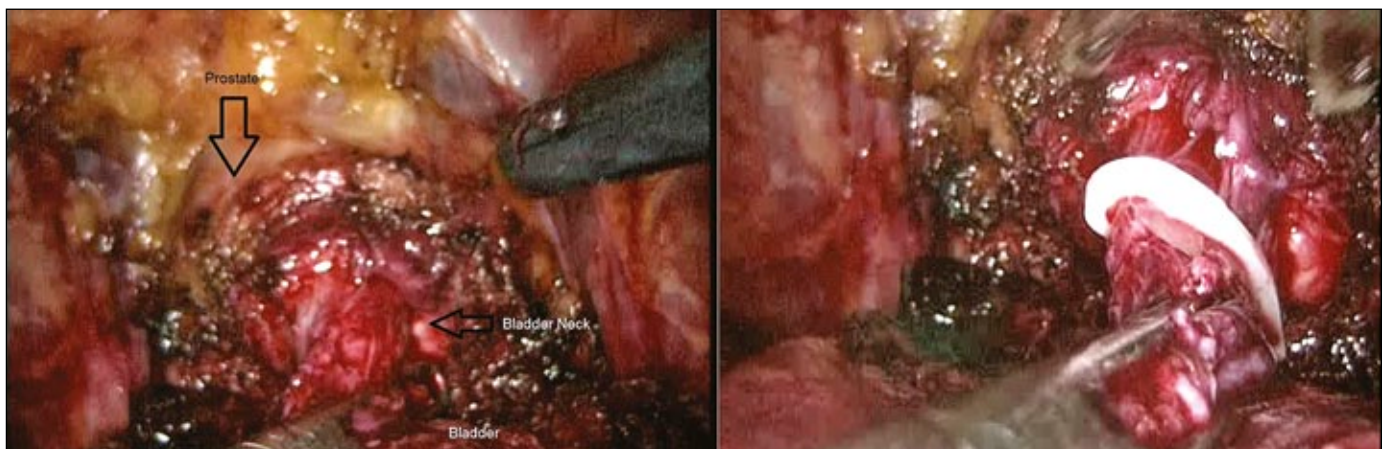


Figure 2. Bladder neck dissection and hem-o-lock placement.

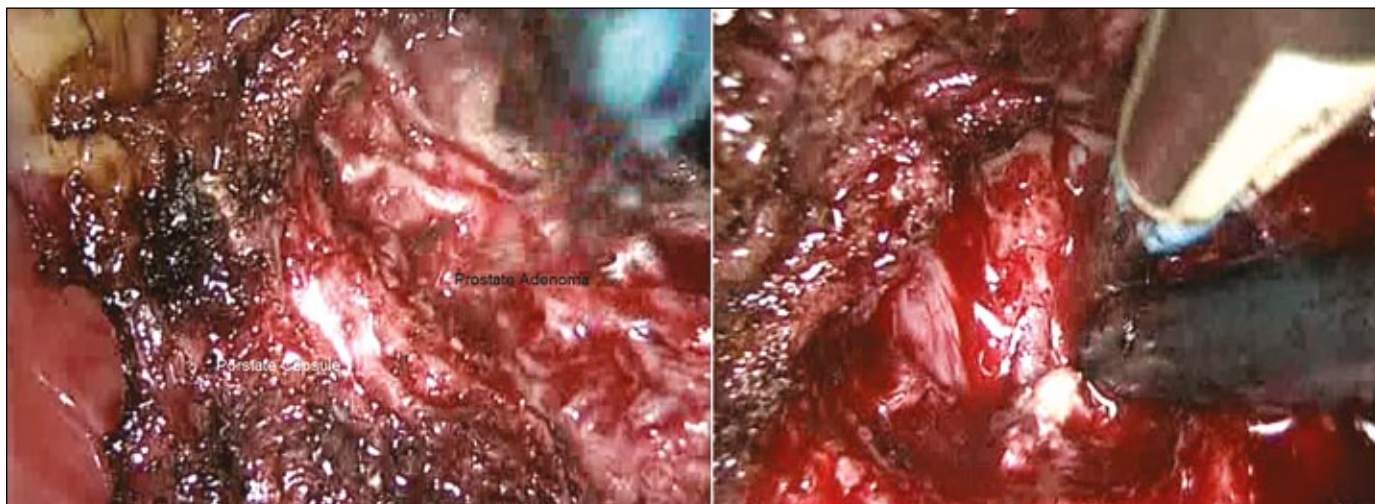


Figure 3. Left: Prostatic adenoma dissection. Right: prostate capsule.

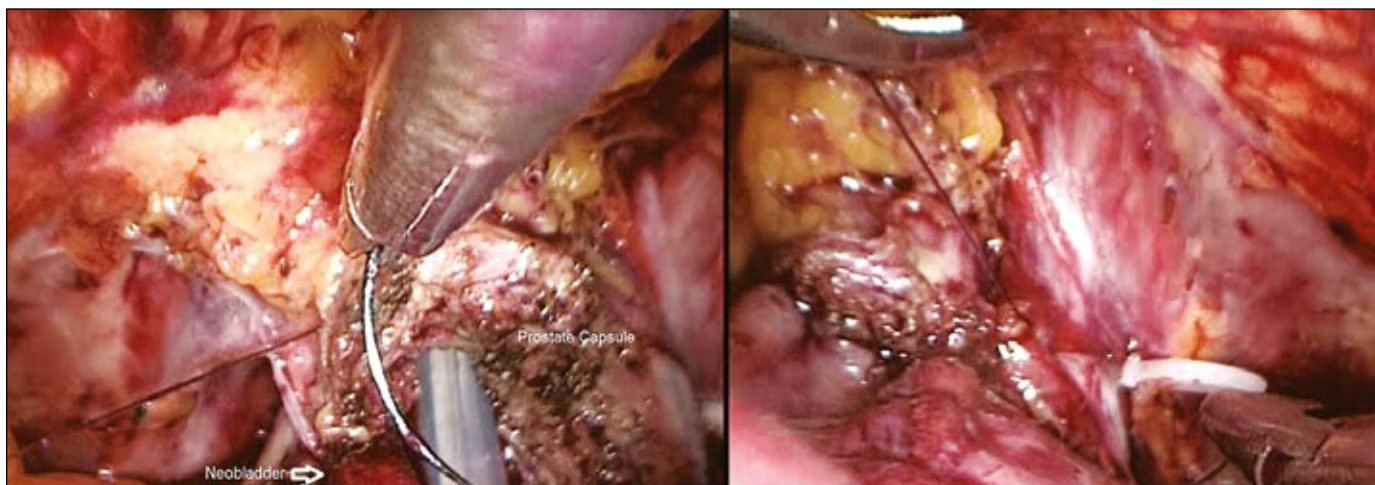


Figure 4. Prostate capsule – neobladder anastomosis.

pedicle is dissected with the help of Ligasure. Later, Retzius space is developed and frees the bladder completely. Then, we proceed to a careful dissection of the bladder neck in the same way as in laparoscopic radical prostatectomy, reaching the level of the seminal vesicles previously developed (Figure 2). After completely dissecting the bladder neck with cuff enough, we proceed to put a hem-o-lock 10 mm and section it; in that way, we guarantee the integrity of the complete bladder, avoiding any risk of tumor dissemination. After releasing the cystectomy specimen, we immediately proceed to the bagging. Then, lymphadenectomy is done following the standard way. Finally, we proceed to perform the prostatic adenomectomy (Figure 3). The cleavage plane is easily identified because the bladder is not present in the surgical field. Finally, we perform a thorough review of hemostasis and do a laparotomy to perform the

intestinal time (7–10 cm long). We proceed to select the intestinal loop and rebuild intestinal transit, the performance of the neobladder, and perform reimplantation of both ureters. When the neobladder is finished, it is reintroduced into the abdominal cavity, pneumoperitoneum is redone after the closure of the laparotomy, and we proceed to the prostatic capsule-neobladder anastomosis (Figure 4). Monocryl 3/0 is used and we perform a continuous suture that starts from the right lateral side of the prostate capsule and urethra to the posterior face of the prostate capsule anastomosing it to the urethra. After the posterior face is performed, the anterior face is done, similar to what is done in radical prostatectomy. Unlike others' neobladder-urethral anastomosis, in some cases it may be necessary to start with another continuous suture for the anterior face to join the posterior face suture.

Follow-up protocol

In the first year, patients are reviewed the first, third, sixth, and twelfth month after surgery, with complete physical examination including digital rectal examination. Urine cytology, complete blood analysis, PSA evaluation, and CT scan of the thorax, abdomen and pelvis are done every 6 months for the first 3 years. If these tests continue to be negative, yearly tests are performed for life.

Continence is assessed according to the number of pads and/or diapers used per day. Patients are considered continent only when they do not use any pads. Sexual function is strictly defined as the ability to maintain an erection sufficient for intercourse with or without medications.

In this study, the 2009 TNM staging system was used [7]. Data has been analyzed statistically at the biostatistics section in our hospital with the SAS Enterprise Guide 3.0 program. Descriptive results are shown in terms of absolute values, mean, median, range, and percentages.

RESULTS

Patient mean age was 58 years (range: 42–67). Mean operative time was 390 minutes (range 360 to 430). Mean operative blood loss was 220 ml. (range 50 to 260). In 4 patients, postoperative paralytic ileus was observed; 3 were resolved with medical treatment (Clavien grade II complication), while the other (1 patient) underwent surgical re-exploration (Clavien grade III complication) and the intraoperative finding was an internal hernia that was repaired. Mean hospital stay was 10.25 days (range: 9–16 days). One case of stricture at the ureteroenteric anasto-

Table 1. Pathological findings

Pathological Stage	n/%
pT0	4/20
pTa – pT1	3/15
pT2	12/60
pT3	1/5
pT4	0/0
Lymph nodes	
N-	19/95
N +	1/5
Pathological grade	
Well differentiated (G1)	2/10
Moderately differentiated (G2)	4/20
Poorly differentiated (G3)	14/70

Table 2. Prostate findings

Prostate	
Adenoma weight	Mean: 31.90 grs (range: 25–42)
	n/%
Bening disease	16/80
Prostate Cancer Gleason 3+2	2/10
Prostate Cancer Gleason 3+3	2/10

Table 3. Functional results

Continenence	n/%
Day	18/90
Night	17/85
Self catheterization	1/5
Sexual Function	
No intercourse	2/10
Intercourse without medication	7/35
Intercourse with medication	11/55
Total	18/90

mosis was diagnosed 6 months after surgery. It was treated by laparoscopic ureteral reimplantation successfully. No prostatovesical junction strictures have been reported to date.

Oncological results

Postoperative pathological features of the surgical specimens are summarized in Table 1. Median follow-up was 36 months (range 12 to 72).

Bladder cancer: No patient had cancer recurrence. Only one patient died of disease progression, in whom the pathological findings was a pT3 pN1 Mx. This patient was diagnosed after the surgery of an immunosuppression disease that we suppose contributed to the cancer progression. No patient died of any other cause.

Prostate cancer

Mean PSA before surgery: 1.3 ng/ml (0.3–2), mean PSA after surgery 1.0 ng./ml (0.08–1.7). Pathology findings of the prostate are summarized in Table 2. No patient had prostate cancer recurrence.

Functional results

Satisfactory daytime and night-time continence was achieved. The results of the functional results are summarized on Table 3. Of the 20 patients, 7 maintained good sexual function without medication and 11 pa-

tients achieved good sexual function with phosphodiesterase-5 inhibitors, making a total of 18 patients, although all of them have retrograde ejaculation.

DISCUSSION

In the 2014 European Association of Urology Guidelines on muscle invasive and metastatic bladder cancer, laparoscopic radical cystectomy is still experimental because of the limited number of cases reported, an absence of long-term oncological and functional outcome data, and a possible selection bias [8]. Laparoscopic treatment of muscle invasive bladder tumors is one of the last surgical approaches to be introduced in our department, partly because of the difficulty of the technique and the especially aggressive behaviour of these tumours. One of the major concerns within the urologic community is to perform a less aggressive surgery (this is possible with the laparoscopic approach) while guaranteeing oncologic results equal to open surgery [5]. Nowadays, after 10 years of experience LRC is the treatment of choice in this pathology at our department. In 2002, Vallencien et al. [2] published their 10-year follow-up results of 100 patients who had prostate sparing cystectomy in their center. Although the functional results were very promising, the lack of a long-term follow-up (81 patients were followed for only 12 months) together with a high incidence of distant metastasis was disappointing.

Despite these results, several groups have published outcomes using prostate-sparing cystectomy in patients with bladder cancer. It is essential to note, however, that all these studies vary widely in several critical aspects of study design. Only a few series limited prostate-sparing to patients with clinically organ-confined urothelial disease (cT2), with some groups including clinical T3/T4 disease [9]. Age limits for prostate-sparing cystectomy also varied, with some studies including men into their 8th decade, increasing the likelihood of both occult prostate cancer and preoperative erectile dysfunction, thereby decreasing the likelihood of functional benefit from prostate-sparing [9]. Screening protocols for occult prostatic malignancy also vary widely, with no consensus presented for this crucial aspect of preoperative risk assessment.

In our series, we show that laparoscopic radical cystectomy with prostate capsule sparing using our selection criteria is an alternative to conventional radical cystoprostatectomy in young patients due to the low bladder cancer recurrence (0 patients) and low bladder cancer progression (1 patient).

Cystoprostatectomy specimens obtained from patients with bladder cancer provide a unique opportu-

nity to assess the features of silent prostate cancer. The frequency of incidentally discovered prostate cancer in these specimens is extremely variable, ranging from 4% in the Lee et al. series [10] to 60% in series published by Winkler et al. [11]. This variability may be explained by several factors, including different pathology sampling techniques. It is widely known that prostate cancer has a great discrepancy between its high prevalence rate and its comparatively low morbidity and mortality rates [12]. In our series, using well selected criteria, we have a very low incidental prostate cancer. In these cases, the choice of therapy is difficult to establish. There are no reports of radical prostatectomy under these conditions, and the frequency of incontinence in these cases is, thus, undocumented. We have not given any additional therapy due to the low risk prostate cancer in the specimens and these patients are being followed with periodic PSA. Following radical prostatectomy, two consecutive values of 0.2 ng/mL or greater appear to represent an international consensus defining recurrent cancer. In prostate capsule-sparing surgery, this criteria cannot be used because part of the prostate is left, so our definition of PCa progression is based in the PSA nadir archived for each patient. A rapidly increasing PSA level (high PSA velocity, short PSA doubling time) may indicate disease progression. Digital rectal examination is also performed to assess whether or not there is any sign of local disease recurrence. A newly detected nodule should raise the suspicion of local disease recurrence. No progression has been diagnosed in our patients.

The incidence of urothelial carcinoma of the prostate ranges from 12% to 48% in cystectomy specimens with stromal invasion present in 7.6–16.6% [13]. However, under-reporting of prostatic involvement is common because most studies lack careful pathologic assessment of the prostate. No urothelial carcinoma of the prostate was diagnosed in our patients. The primary goal of laparoscopic prostate-sparing cystectomy for bladder cancer in our series is to optimize postoperative functional results for continence and sexual function while always preserving the oncological principles. Continence rates following prostate sparing cystectomy are impressive in most series [14, 15, 16]. In our patients after catheter removal, daytime continence was achieved in 65%, and nighttime continence in 50%. After 1 year, almost 90% of patients were dry during day and night. Nonetheless, it must be noted that validated questionnaires were not routinely used to assess continence or potency in our series, as in almost of the rest of the series published. The effect of prostate sparing radical cystectomy on sexual function is a rarely investigated

matter. The recovery rate of erectile function ranges from 14–100% using a nerve-sparing technique with or without saving the prostate. We archived 90% of good sexual function with or without medications after this procedure. This important functional result makes an improvement of the quality of life of patients. A direct comparison between techniques is of questionable value, because a stricter definition of risk factors, pathologic stage, selection criteria, length of follow-up, and definition of sexual function is needed in this kind of study. Selection criteria for prostate-sparing cystectomy performed by an expert committee or the usages of validated questionnaires for assess functional results may solve this problem. The present study had several limitations. There were few patients included and the patients have a short follow up; however, it is one of the few describing results regarding laparoscopic radical cystectomy with prostate capsule sparing. Most of the largest series published describe open procedures, and it is well known that the laparoscopic approach in radical cystectomy has demonstrated significant improvements in intraoperative blood loss and length of stay without significant increase in complications [16, 17, 18]. We believe that the good vision of the pelvis in the Trendelenburg position leads us to the capacity of performing a good hemostasis inside the prostate capsule with bi-polar grasping instruments. From the oncological point of view, more time is needed to compare results with the open proce-

dures, but early oncological outcomes are comparable with open surgery series. This study further supports the need for randomized trials comparing open and laparoscopic procedures.

CONCLUSIONS

Prostate-sparing cystectomy remains one of the most controversial topics in urology today. A population of relatively young, otherwise healthy men with good erectile function and high risk non-muscle invasive bladder cancer who might be resistant to radical cystectomy would be the ones most likely to benefit from prostate-sparing cystectomy, presuming that these critically important oncologic concerns may be properly addressed. The laparoscopic approach could be an alternative to conventional radical cystoprostatectomy in well selected patients, done in experienced institutions in order to find better functional results, with a low disease progression and recurrence rate.

CONFLICTS OF INTEREST

The authors declare no conflicts of interest.

ACKNOWLEDGMENTS

The authors thank the anesthesiology and reanimation department, especially Dra. Ana Reguera and Dr. Rafael Uña, for their support in the performance of this surgical procedure. We also would like to thank our secretary for her administrative work.

References

- Hart S, Skinner EC, Meyerowitz BE, Boyd S, Lieskovsky G, Skinner DG. Quality of life after radical cystectomy for bladder cancer in patients with an ileal conduit, or cutaneous or urethral Kock pouch. *J Urol.* 1999; 162: 77-81.
- Vallancien G, Abou EF, Cathelineau X, Baumert H, Fromont G, Guillonnet B. Cystectomy with prostate sparing for bladder cancer in 100 patients: 10-year experience. *J Urol.* 2002; 168: 2413-2417.
- Botto H, Sebe P, Molinier V, Herve JM, Yonneau L, Leuret T. Prostatic capsule and seminalsparing cystectomy for bladder carcinoma: Initial results for selected patients. *BJU Int.* 2004; 94: 1021-1025.
- Hautmann RE, Hautmann O, Volkmer BG, Hautmann S. Nerve-sparing Radical Cystectomy: A New Technique. *Eur Urol Suppl.* 2010; 9: 428-432.
- Cansino JR, Cisneros J, Alonso S, Martínez-Piñeiro L, Aguilera A, Tabernero A, et al. Laparoscopic Radical Cystectomy: Initial Series and Analysis of Results. *Eur Urol Suppl.* 2006; 5: 956-961.
- Gómez Rivas J, Alonso y Gregorio S, López Sánchez D, Tabernero Gómez A, Cisneros Ledo J de la Peña Barthel J.J. Laparoscopic radical cystectomy with prostate capsule sparing. Oncologic and functional results: Our experience. *Eur Urol Suppl.* 2013; 12: e1036.
- Sobin LH, Gospodariwicz M, Wittekind C. TNM classification of malignant tumors. UICC International Union Against Cancer. 7th edn., New York, Wiley-Blackwell, 2009, pp. 262-265.
- Witjes JA, Compérat E, Cowan NC, et al. EAU guidelines on muscle-invasive and metastatic bladder cancer: summary of the 2013 guidelines. *Eur Urol.* 2014; 65: 778-792.
- Kefer, JC, Campbell, SC. Current status of prostate-sparing cystectomy. *Urol Oncol.* 2008; 26: 486-493.
- Lee SH, Chang PL, Chen SM, et al. Synchronous primary carcinomas of the bladder and prostate. *Asian J Androl.* 2006; 8: 357-359.
- Winkler MH, Livni N, Mannion EM, Hrouda D, Christmas T. Characteristic of prostatic incidental adenocarcinoma in contemporary radical cystoprostatectomy specimens. *BJU Int.* 2007; 99: 554-558.
- Damiano R, Di Lorenzo G, Cantiello F, et al. Clinicopathologic features of prostate adenocarcinoma incidentally discovered at the time of radical cystectomy: an evidence-based analysis. *Eur Urol.* 2007; 52: 648-657.
- Palou J, Baniel J, Klotz L, et al. Urothelial carcinoma of the prostate. *Urology.* 2007; suppl 1: 50-61.

14. Arroyo C, Andrews H, Rozet F, Cathelineau X, Vallancien G. Laparoscopic Prostate-Sparing Radical Cystectomy: The Montsouris technique and preliminary results. *J Endourol.* 2005; 19: 424-428.
15. Muto G, Collura D, Rosso R, Giacobbe A, Muto GL, Castelli E. Seminal-sparing cystectomy: technical evolution and results over a 20-year period. *Urology.* 2014; 83: 856-861.
16. Mertens LS, Meijer RP, de Vries RR, et al. Prostate sparing cystectomy for bladder cancer: 20-year single center experience. *J Urol.* 2014; 191: 1250-1255
17. Yu HY, Hevelone ND, Lipsitz SR, et al. Comparative analysis of outcomes and costs following open radical cystectomy versus robot-assisted laparoscopic radical cystectomy: results from the US Nationwide Inpatient Sample. *Eur Urol.* 2012; 61: 1239-1244.
18. Styn NR, Montgomery JS, Wood DP, et al. Matched comparison of robotic-assisted and open radical cystectomy. *Urology.* 2012; 79: 1303-1308. ■