

Cystolithiasis in women as a distant complication after minimal invasive treatment of stress urinary incontinence

Mariusz Blewniewski, Michał Markowski, Rafał Kliś, Waldemar Róžański

2nd Department of Urology, Medical University of Łódź, Poland

Article history

Submitted: March 20, 2014

Accepted: June 14, 2014

Correspondence

Mariusz Blewniewski
2nd Department of
Urology
Medical University of Łódź
62, Pabianicka Street
93–513 Łódź, Poland
phone: +48 42 689 52 11
urologia@poczta.onet.pl

Introduction Stress urinary incontinence (SUI) is a condition of social dimension which generally pertains to women of various age. The only effective treatments of SUI are surgical procedures. The use of tension-free vaginal tape (TVT) ensures low invasiveness but also carries the risk of complications. One of the complications may be migration of the tape into the urinary bladder creating conditions for urinary stones. There is a number of treatment methods for cystolithiasis, among them the optical lithotripter, ultrasound and pneumatic probes, and recently, the holmium laser.

Material and methods From January 2009 to February 2010, six women suffering from bladder stones were treated at our department. All patients had previously undergone SUI procedures and over time, thread or tape had penetrated into the urinary bladder. The stone diameters were in the range of 1.6 cm–3.5 cm. Lithotripsy was performed with the use of an 80 W holmium YAG laser as an endoscopic procedure: beam frequency length of 2100 nm and applied energy was in the range of 0.2–3.5 J.

Results The urinary bladder stones were disintegrated and suctioned out. During the same procedure, the threads or tape from the SUI procedure were excised from the bladder. All patients were discharged from the hospital in good general condition after two days.

Conclusions The holmium laser is an effective treatment for patients with bladder stone complications after SUI procedures when threads or tape have migrated and penetrated the bladder wall. The procedure is straightforward and safe for patients.

Key Words: stress urinary incontinence ◊ complications ◊ minimally invasive method ◊ holmium laser

INTRODUCTION

Stress urinary incontinence (SUI) affects about 27.6% (4.8 to 58.4%) of women [1]. Women of various age confront this difficult and personal problem – at age 25, about 10% of women; at age 80, over 40%. Clinical observations seem to indicate that women in their 50's and 80's develop the syndrome most frequently [2]. Pharmacological treatment for SUI has little impact and open surgery carries a higher risk of complications, thus this treatment was generally rejected by the patients. Improved treatment appeared with the Pereyra–Stamey, and Zoedler methods where the premise of the procedure was to raise the tissue of the bladder neck by the use of long

sutures connected to the abdominal muscle fascia. The operation is carried out from the side of the vagina. Favorable results were seen in approximately 85% of the cases. The last 20 years have produced further modifications and improvements for procedures in the treatment of SUI e.g. materials used for the manufacturing of tapes are better absorbed, have fewer complications, and are better tolerated by women. New tapes are implemented under the mid-urethra which makes them more safe for women. Tension-free vaginal tape (TVT) was introduced to treat women suffering from SUI where the urethral sphincter is suspended by tape attached to the pubic symphysis just above the vagina (rectopubic). The transobturator tape (TOT) technique is based

Table 1. Method of SUI treatment according to patient age, bladder stone diameter and time span from the procedure

Procedure choice	Number of patients	Patient ages (years)	Time span from procedure (months)	Diameter of stone (mm)
TVT implantation	4	57–71 (average 64)	12 to 24 (average 19)	16 to 30 (average 23)
Pereyra procedure	2	47–56 (average 51.5)	12 to 192 (average 104)	17 to 35 (average 26)

on use of the obturator foramen [3]. The new methods insure minimally invasive surgery, yet they may still incur complications. The Pereyra–Stamey–Raz needle approach and the TVT system may cause bladder wall damage, urination difficulty resulting from urethral blockage, and less frequently, damage to the urethral sphincter, intestines, blood vessels or nerves, and erosion of the vaginal wall. One complication observed over longer periods of time after SUI surgical procedures is the migration of threads or tape and penetration of the bladder wall and progressive formation of calculi which can become significant and fused with the thread(s) and/or tape. The frequency of urethral sphincter or bladder wall erosion after surgical procedures, based on long-term analysis, is approximately 2.5% [4]. Total complications after tape application may reach 30% [5, 6]. If the tape or thread(s) do not migrate to the urethral sphincter, the resulting stones do not create urination problems. Those patients with bladder stones attached to the bladder wall complain of pain during urination, incontinence, bladder bleeding, lumbar pain, and recurrent urinary tract infection [7,8]. Diagnosed stones require medical treatment which involves disintegration and removal of said stones and the excision of threads and/or tape that have penetrated the bladder wall. For these treatments, optical extracorporeal shock wave lithotripsy (ESWL) apparatus, ultrasound probes, pneumatic lithoclast apparatus, and recently, a holmium laser have been used [9, 10, 11]. This latest technique not only effectively disintegrates the bladder stones, but also efficiently excises tape and thread fragments which have found their way into the interior of the bladder. In this way, the additional utilization of laparoscopic scissors or resectoscope is avoided.

MATERIAL AND METHODS

The objective of this study is to assess the effectiveness of the Holmium/Yttrium Aluminum Garnet (Ho:YAG) laser (in the form of the Omni Puls – MAX™ Holmium

Laser), in disintegrating bladder stones resulting from the migration and penetration of the bladder wall by threads and/or tape used to treat stress urinary incontinence (SUI) through minimally invasive surgery utilizing surgical thread and/or various types of tape.

Between January 2009 and February 2010, six women were admitted to the 2nd Clinic of Urology, Medical University of Łódź (Poland) for treatment of bladder stones. These stones appeared on migrated surgical threads and/or tapes in the bladder after procedures for SUI. Two of the patients had undergone the Pereyra procedure; the other four, ‘tension-free’ tape (TVT) implantation. One of the patients had cystolitholapaxy procedures twice after TVT implantation (Table 1).

The age of the patients treated using the Pereyra method ranged between 47 and 56 years (average 51.5), and those treated by TVT ranged from 57 to 71 years (average 64). The time span between SUI procedure and bladder stone treatment for women treated by the Pereyra method was 8.5 years and 1.7 years for TVT treated women. The diameter of the stones ranged from 1.7 to 3.5 cm (average 2.6) for the Pereyra method treated women and 1.6 to 3.0 (average 2.3) cm for the TVT treated women (Table 2). Stone disintegration through the use of the Ho:YAG laser was performed endoscopically; the stones were fragmented and suctioned out, followed by thread and/or tape excision from the interior of the bladder. The holmium laser was rated at 80 W and the length of the light-ray was 2,100 nm. The range of applied energy ranged from 0.2 to 3.5 J, and frequency from 5 to 60 Hz. The optic fiber used for stone fragmen-

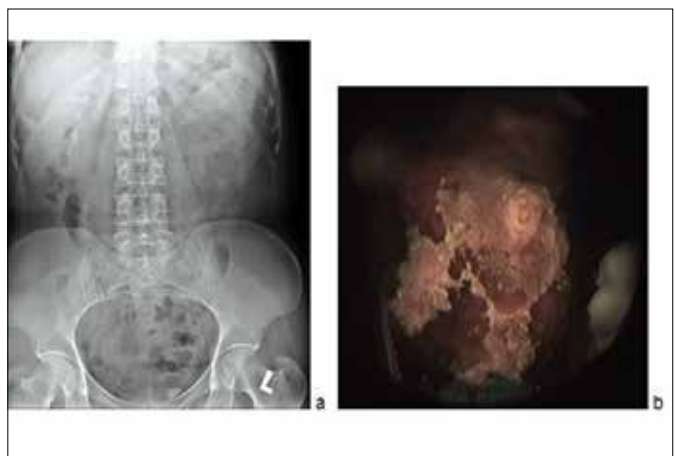

Figure 1. A. Intravenous pyelography with visible stone in the urinary bladder on the left side. B. Endoscopic image of a stone in the bladder. Patients after tension-free vaginal tape implantation.

tation and thread/tape excision was the Flex MAX™ Holmium Laser Fiber with diameters of 200 µm, 365 µm, and 550 µm, according to the stone's diameter. The procedures were carried out under spinal or short-term intravenous anesthesia.

RESULTS

X-ray imaging and cystoscopy were used for initial diagnosis followed by endoscopic examination of the bladder for confirmation (Figure 1).

In all the patients, the stones were disintegrated and suctioned out, and the threads or tape fragments in the bladder were excised by the same optic fiber. After two days of observation, the patients were discharged in generally good health with no after effects.

The time to perform the procedure – fragmenting and removing the stones, excising and removing migrated fragments of TVT from the bladder – took from 30 to 60 (average 50) minutes; whereas the procedure for Pereyra method patients (fragmenting and removing stones, excising and removing migrated threads from the bladder) required 30 to 60 (average 45) minutes. Consumed power for frag-

menting stones and excising TVT fragments from the bladder varied from 0.723 to 6.594 (average 4.133) J; whereas for the Pereyra method patients, 0.252 to 3.452 (average 1.85) J. For the procedure of stone fragmentation and TVT excision, 200 µm, 365 µm, and 550 µm diameter laser fiber was utilized and 365 µm and 550 µm diameter laser fiber was utilized for thread penetration of Pereyra method treated patients (Table 2).

DISCUSSION

The procedure for disintegrating stones and excising tape or threads in the bladder with the use of endoscopy is straightforward and safe. Nevertheless, it bears mentioning that there is a risk of perforating the bladder wall (resulting in urine seepage into surrounding tissue or the peritoneum) when operating the laser optic fiber in close proximity to said wall. Stone fragments, TVT or thread fragments are easily evacuated from the bladder (Figures 2–5).

Various authors offer several methods for treating bladder stones resulting from migrated TVT into the bladder – from optical lithotripsy to lithoclasts to lasers. In the case of TVT fragment removal, current

Table 2. Parameters of laser lithotripsy for bladder stone disease in patients after SUI surgery

Performed treatment for SUI procedure	Implanted TVT for 4 patients	Pereyra procedure for 2 patients
Time required for stone fragmentation/removal and TVT/thread fragment excision/removal	30 to 60 (average 50) minutes	30 to 60 (average 45) minutes
Consumed power (J)	0.723 to 6.594 (average 4.133) J	0.252 to 3.452 (average 1.85) J
Flex MAX™ Holmium Laser Optic Fiber diameter	2 x 550 µm 1 x 365 µm 1 x 200 µm	1 x 365 µm 1 x 550 µm




Figure 2. The stone on threads after Pereyra operation. Threads migrated into the bladder. It was disintegrated and threads were cut off with a holmium laser as endoscopic procedure.

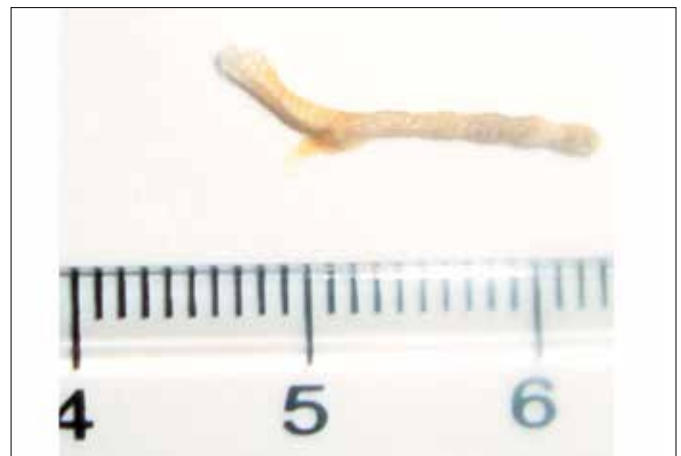

Figure 3. A piece of thread excised from the bladder of the patient who underwent Pereyra procedure.



Figure 4. Stone and part of the tape after removal from the bladder by using holmium laser on as endoscopic procedure.



Figure 5. Part of the tape with a few small stones on the surface after removal from the bladder by using holmium laser as endoscopic procedure.

literature mentions the application of electroresection [9, 10, 11]. In these cases the opportunity to perform two procedures with the Ho:YAG laser was taken i.e. to disintegrate stones anchored to tape or thread fragments in the bladder and to excise said fragments.

Doumouchtsis et al. presented results of treatment of six women with complications after continence operations. The mesh or suture was excised from the bladder using a holmium laser. Authors achieved very good results in all cases. The mesh or suture was completely removed from the bladder. In the authors' opinion, endoscopic excision using the holmium laser can be the first line treatment in complications after continence surgery [12].

The 2nd Clinic of Urology, Medical University of Łódź (Poland) has disintegrated urinary tract stones for several years utilizing an 80 W Ho:YAG laser, with very high effectiveness. This laser was then applied to the treatment of bladder stones resultant from delayed complications after treatment of SUI

in women. The advantage of the laser is the simultaneous opportunity to precisely fragment bladder stones and excise migrated TVT or thread fragments into the bladder. These procedures do not require open surgery as they are performed endoscopically.

CONCLUSIONS

The utilization of the Ho:YAG laser is effective in excising migrated surgical thread and TVT fragments which have penetrated the bladder wall and formed calculi after procedures for suspending the urethral sphincter. Disintegrating the stones is straightforward, and excising tape or thread fragments has become a procedure, which is less invasive and more effective than methods applied up to this time. Endoscopy, coupled with the Ho:YAG laser, is a worthy endorsement in the treatment of calculi as a complication of SUI treatment procedures.

References

1. Minassian VA, Drutz HP, Al.-Badr. Urinary incontinence as a worldwide problem. *Int J Gynecol Obstet.* 2003; 82: 327–338.
2. Hannestad YS, Rortveit G, Sandvik H, Hunskaar S. A community – based epidemiological survey of female urinary incontinence: the Norwegian EPINCONT study. *J Clin Epidemiol.* 2000; 53: 1150–1157.
3. Mellier G, Benayed B, Bretones S, Pasquier JC. Suburethral tape via the obturator route: Is the TOT a simplification of the TVT? *Int Urogyn J.* 2004; 15: 227–232.
4. Levin I, Groutz A, Gold R, Pauzner D, Lessing JB, Gordon D. Surgical complications and medium-term outcome results of tension-free vaginal tape: a prospective study of 313 consecutive patients. *Neurourol. Urodyn.* 2004; 23: 7–9.
5. Debodinance P, De Bièvre P, Parmentier D, Dubrulle R, Querleu D, Crépin G. The “hazards” of using a Gore-Tex sling in the treatment of stress urinary incontinence. *J Gynecol Obstet Biol Reprod (Paris).* 1994; 23: 665–670.
6. Bent AE, Ostergard DR, Zwick-Zaffuto M. Tissue reaction to expanded polytetrafluoroethylene suburethral sling for urinary incontinence: clinical and histologic study. *Am J Obstet Gynecol.* 1993; 169: 1198–1204.
7. Huwyler M, Springer J, Kessler TM, Burkhard FC. A safe and simple solution for intravesical tension-free vaginal tape erosion: removal by standard transurethral resection. *BJU Int.* 2008; 102: 582–585.
8. Tolosa Eizaguirre E, Rincón Mayans A, Zuazu JR, Bergera JJ, Abad JB, Polo JM.

- Development of bladder stone following a tension-free vaginal tape procedure: a case report. *Actas Urol Esp.* 2009; 33: 700–702.
9. Oh TH, Ryu DS. Transurethral resection of intravesical mesh after midurethral sling procedures. *J Endourol.* 2009; 23: 1333–1337.
10. Mustafa M, Wadie BS. Bladder erosion of tension-free vaginal tape presented as vesical stone: management and review of literature. *Int Urol Nephrol.* 2007; 39: 453–455.
11. Feiner B, Auslender R, Mecz Y, Lissak A, Stein A, Abramov Y. Removal of an eroded transobturator tape from the bladder using laser cystolithotripsy and cystoscopic resection. *Urology.* 2009; 73: 681.
12. Doumouchtsis SK, Lee F, Bramwell D, Fynes M. Evaluation of holmium laser for managing mesh/suture complications of continence surgery. *BJU Int.* 2011; 108: 1472–1478. ■