

# Advances in urethral stricture diagnostics and urethral reconstruction beyond traditional imaging: a scoping review

Hoi Pong Nicholas Wong<sup>1</sup>, Wei Zheng So<sup>1</sup>, Khi Yung Fong<sup>1</sup>, Ho Yee Tiong<sup>1</sup>, Sanjay Kulkarni<sup>2</sup>, Daniele Castellani<sup>3</sup>, Bhaskar Somani<sup>4</sup>, Vineet Gauhar<sup>5</sup>

<sup>1</sup>Department of Urology, National University Hospital, Singapore

<sup>2</sup>Kulkarni Reconstructive Urology Centre, Pune, India

<sup>3</sup>Urology Unit, Azienda Ospedaliero-Universitaria delle Marche, Università Politecnica delle Marche, Ancona, Italy

<sup>4</sup>Department of Urology, University Hospital, Southampton, United Kingdom

<sup>5</sup>Department of Urology, Ng Teng Fong General Hospital, Singapore

**Citation:** Wong HPN, So WZ, Fong KY, et al. Advances in urethral stricture diagnostics and urethral reconstruction beyond traditional imaging: a scoping review. Cent European J Urol. 2024; doi: 10.5173/ceju.2024.121 [Epub ahead of print]

## Article history

Submitted: May 23, 2024

Accepted: May 26, 2024

Published online: Sept. 30, 2024

## Corresponding author

Hoi Pong Nicholas Wong  
House Officer  
Department of Urology,  
National University Hospital  
5 Lower Kent Ridge Road,  
Singapore 119074  
nichwong9@gmail.com

**Introduction** Urethral stricture disease is considered one of the more functionally bothersome aspects of urological conditions. The management of such disease is also traditionally managed with urethroplasty, or in severe cases, reconstruction. With the rise of artificial intelligence (AI) playing its part in diagnostics and treatment of urological conditions, we sought to determine its use case in urethral conditions in today's era of advanced surgical care.

**Material and methods** A comprehensive literature search was performed to identify literature on advances in diagnosis and management of urethral strictures. Publications in English were selected, whilst studies that were case reports, abstracts only, reviews, or conference posters were excluded.

**Results** Twelve studies were finalised for review. Conventional neural networks and computational fluid dynamics implemented in retrograde urethrography reduced false positive and negative rates of urethral stricture diagnosis. Four-detector row computed tomography and magnetic resonance imaging voiding with virtual urethroscopy are also emerging imaging combination options for identification, offering decreased duration needed for diagnosis and increased correlation with intra-operative findings of urethral stricturing. For tissue re-engineering for urethral strictures, the role of 3-dimensional bioprinting of both autologous and allogenic sources has been on the rise, with promising findings of sustained tissue viability demonstrated in several *in vitro* animal studies and showing potential for expansion into human utilisation.

**Conclusions** Advances in detection and management of urethral strictures have steadily been increasing its capacity, especially with the rise in artificial AI-driven learning algorithms and more accurate objectivity. Further studies are awaited to validate the use case of AI models in fields of urethral stricturing disease.

**Key Words:** radiomics ↔ artificial intelligence ↔ 3D printing ↔ urethral strictures

## INTRODUCTION

Urethral stricture disease (USD) is an abnormal narrowing of the urethral lumen, causing significant restriction of urine flow from the bladder [1]. This significantly impacts the patient's well-being and quality of life [2], and leads to further complications ranging from obstructed urinary flow, acute

retention of urine, recurrent urinary tract infections and calcifications, and even post-renal nephropathy in advanced cases if left untreated [3]. Causes of urethral strictures are multifactorial, encompassing iatrogenic origins in more developed countries and infective or traumatic causes in less well-resourced countries [4]. Traditional gold standard diagnostic modalities include retrograde

urethrography (RUG) and urethroscopy, allowing both radiographic and endoscopic visualisation [5]. However, RUG has been shown in multiple studies to potentially damage the urethral mucosa, over/underestimate the length of stricture, and even potentially missing the diagnosis of a urethral stricture [6, 7]. In addition, performing the RUG requires the distal urethra to be patent for the catheter to be threaded through [8]. In this instance, the use of magnetic resonance imaging (MRI) combined with urethrograms has shown much promise both diagnostically and in surgical planning [9].

The management of urethral strictures involves a spectrum of interventions, ranging from minimally invasive techniques, such as endoscopic dilation incisions, to urethral reconstruction using tissue grafts [10]. The choice of treatment is a delicate interplay between patient, disease, and surgeon factors. Whilst traditional approaches have shown success, they may also be associated with complications, prolonged recovery periods, and even failure at times [11, 12].

There is an increasing trend in the utility of 3D imaging, artificial intelligence (AI), machine learning, and even radiomics in urology [13–15]. Machine learning-based imaging algorithms have grown leaps and bounds in recent years, showing great potential in diagnosing initially hard to spot diagnoses [16]. The ability to merge cross sectional imaging with AI to form a virtual endoscope has also aided in the diagnostic processes of many conditions [17]. With the advent of 3D imaging, accurate depiction of pathology and consequent reconstruction allows for optimal surgical planning, which would have initially been impossible without these technologies [18, 19]. 3D printing can also be utilised to accurately produce models that not just aid in the training and simulation phase [20], but the bioprinting component can also be used to replace and repair resected organs, such as the bladder in cases of cystoplasty [21].

Our scoping review aims to evaluate the recent advances in both diagnosis and management of urethral strictures, with particular focus on novel technological advancements – such as AI-powered algorithms and newer 3D imaging techniques, computerised simulation models, as well as the role of bioengineering.

## MATERIAL AND METHODS

A comprehensive literature search was carried out on 19 July 2023, by 2 independent reviewers (NHPW and KYF) across the PubMed, EMBASE, and Web of Science databases with the search terms and Boolean operators optimised to search

for “Urethral Strictures”, “Urethral Reconstruction”, “Urethroplasty”, “Artificial Intelligence”, “Radiomics”, “Machine Learning”, “Deep Learning”, “Neural Networks”, “Algorithm”, and “tree-based” amongst others. The titles and abstracts were then screened for potential relevance, and the full texts of these articles were then further assessed for eligibility. The inclusion criteria for this review required studies to investigate or report advances in urethral stricture diagnosis or management in the fields of AI, machine learning, 3D printing, and radiomics-based applications. Studies that were non-English, case reports, abstracts only, reviews, and conference posters were excluded. The data were then extracted narratively using a standard data collection template with pre-defined data fields including study characteristics, objective of study, study findings, and conclusions.

## RESULTS

### Search results

The search strategy yielded 1,025 articles, and after removal of 389 articles, 636 titles and abstracts were selected for screening. Twenty-five articles were assessed for full-text review, of which the final review included 12 articles (Figure 1). The included studies are shown in Table 1.

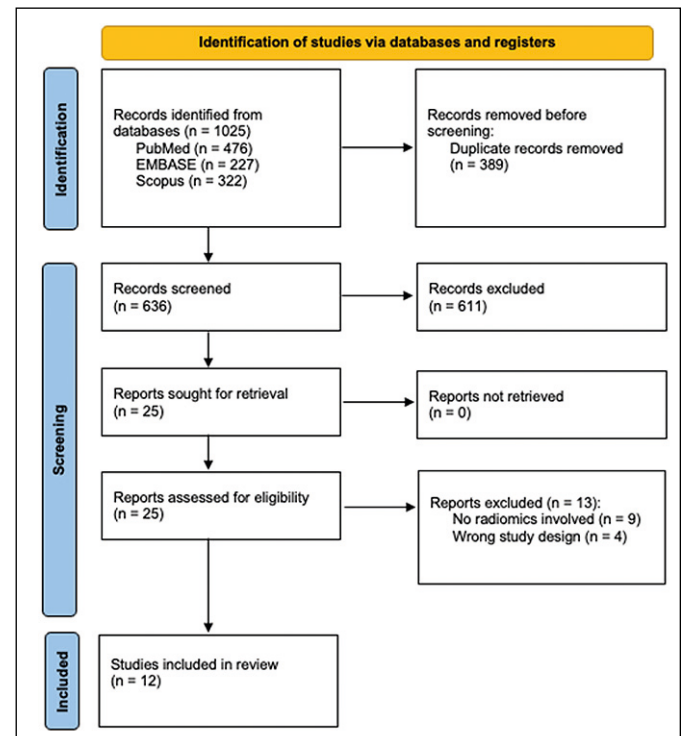


Figure 1. PRISMA 2020 Flow Diagram.

**Table 1.** Summary of included studies

Authors (year), ref.	Type of study	Diagnostic (D)/ Management (M)/ Bioengineering (B)	Summary of findings	Conclusion
Eun et al. (2022) [25]	<i>In vivo</i>	D	ResNet-50 algorithm can recognise and guide endoscopic operators to exactly where they are on the urethra and where the stricture is with a sensitivity of 0.961, false positive of 0.238, and false negative of 0.0290	The system uses real-time endoscopic imaging to guide and instruct surgeons during surgery with a high degree of sensitivity, allowing surgeons to accurately detect stenosis
Tsang et al. (2020) [34]	<i>In vivo</i>	D	MRI radiomics features can help predict if post-HDR brachytherapy patients will attain urethral strictures with features such as pre-operative contrast and homogeneity showing statistically significant differences	MRI Radiomic features can possibly identify patients who are more prone to developing urethral strictures post HDR BT. Extracting these radiomic features from the staging MRI can potentially benefit prostate cancer patients by providing an extra risk stratification
Kim et al. (2022) [26]	<i>In vivo</i>	D	CNN-based machine learning algorithms can help characterise retrograde urethrogram images between those with and without strictures to a validated accuracy of 0.885 for the testing set	It has good potential in aiding junior urologists identify, in a binary fashion, whether or not a stricture is present. Further training can help improve imaging recognition and development of more complex schemes such as characterisation of stricture location and length to suggest optimal operative approaches for repair
Cohen et al. (2019) [37]	<i>In vitro</i>	D	Computational fluid dynamics is plausibly feasible and applicable in the modelling urine flow. Flow rates from the CFD model are consistent with uroflowmetry values found in the literature	CFD models have been validated and recommended in clinical guidelines for the use in cardiology, such as in CT-derived fractional flow reserve. Given that there are inherent similarities between fluid flow in the CVS and urinary tract, CFD may be a useful adjunct for research and clinical practice
Hanna et al. (2011) [32]	<i>In vitro</i>	D	4-detector row CT can scan the entire urethra and bladder in 10 seconds with easy complete evaluation of the entire urinary tract, with images that are better appreciated than on conventional urethrograms and RUG. Images from CT can also be combined to become CT virtual urethroscopy, which is easily interpreted by radiologists and urologists who may not be familiar with transverse images in association with multidirectional viewing	If RUG cannot be tolerated by the patient, urethral imaging with CT VU and virtual endoscopy can reduce organ injury and patient inconvenience whilst still providing excellent imaging  CT VU in combination with CT RUG and virtual urethroscopy produces accurate measurement of lesions without distortion. With good compliance and patient selection, this enables us to survey the whole urinary tract well
Yekeler et al. (2004) [35]	<i>In vivo</i>	D	Contrast-enhanced MRVU with 3D MRA technique is a feasible modality in diagnosing urethral strictures, with an accuracy of 1.00. In some cases, severe strictures were better demonstrated on the CE 3D MRVU than on conventional diagnostic modalities. The technique also helped diagnose strictures in patients with far distal urethral strictures who could not have had retrograde urethrograms performed	CE 3D MRVU can be used to successfully assess the entire urethra, which can be helpful and potentially more accurate in diagnosing strictures in select cases
Lv et al. (2016) [33]	<i>In vivo</i>	D	CT VU has significant clinical utility in detecting urethral strictures, picking up more surgically diagnosed strictures when compared to conventional urethrography and cystourethroscopy. Also, it was shorter in duration, had a higher concurrent fistula detection rate, and had higher correlation with intra-operative findings	CT VU and virtual endoscopy provides a global orientation for focal findings and aids in navigation for endoscopists. This may be a promising imaging technique for the evaluation of urethral strictures. CT VU can also be utilised in patients who cannot tolerate excessive positional manipulation, such as in those with severe pelvic fractures
Cohen et al. (2020) [26]	<i>In vitro</i>	D	Urinary spray patterns and flow rate can help to identify urinary occlusion	No <i>in vivo</i> extension in diagnosing urethral strictures in humans

Table 1. Continued

Authors (year), ref.	Type of study	Diagnostic (D)/ Management (M)/ Bioengineering (B)	Summary of findings	Conclusion
Zhang et al. (2023) [40]	<i>In vitro</i>	M	3D-printed models of pelvic fracture urethral injury associated urethral strictures aids in patient education, was able to accurately reflect key anatomical considerations, and aided significantly in perioperative assessments and planning	3D-printed models can be utilised greatly for patient education and preoperative planning for complex cases
Joshi et al. (2020) [41]	<i>In vitro</i>	M	3D-printed models of pelvic fracture urethral injury associated urethral strictures were subjectively thought to be more useful in helping surgeons make perioperative assessments, especially with regards to the requirements of inferior pubectomy, to bridge the gap between the proximal and distal urethra. Objectively, the anatomical injuries as seen in the 3D models help to shorten surgical time	3D-printed models have the potential to be used as training tools for young surgeons and for preoperative planning for complex cases
Zhang (2017) [45]	<i>In vitro</i>	B	3D bioprinting technology fabricated cell-laden urethras <i>in vitro</i> using polycaprolactone and polylactide-co-caprolactone polymers in a spiral scaffold design had high tensile strengths, high young's' modulus values, and were close to native rabbit urethra mechanical properties. It also had the potential to mimic a natural urethral base-membrane, facilitating contact and cell growth with printed cells. The cell-laden fibrin-based hydrogels also had a suitable microenvironment for cells to proliferate and express cell-specific biomarkers over time	50/50 Polycaprolactone and polylactide-co-caprolactone polymer scaffolds with cell-laden fibrin-based hydrogels is an adequate environment for cellular proliferation and viability, especially for bioengineering urethra tissue and structure in rabbits. There is potential expansion into human <i>in vitro</i> use for the treatment of urethral strictures
Huang et al. (2015) [46]	<i>In vitro</i>	B	3D porous bacterial cellulose scaffold seeded with lingual keratinocytes in a rabbit model is a viable option for urethral reconstruction. At 3 months post op, all urethras maintained wide calibres and did not develop strictures	The scaffold had good biocompatibility with lingual keratinocytes and improved urethral tissue regeneration with low inflammatory reactions. This is a promising alternative scaffold for urethral reconstruction

CFD – computational fluid dynamics; CNN – convolutional neural network; CT VU – computed tomography with voiding urethrography; MRVU – magnetic resonance with voiding urethrography, RUG –retrograde urethrography

## Diagnostics

### Artificial intelligence and machine learning

The current gold standard for diagnosing and staging USD is retrograde urethrogram (RUG) [22]. By injecting water-soluble contrast into the urethra, the urethral lumen is assessed via direct fluoroscopic imaging. It has garnered appraisal in its ability to diagnose, characterise, and localise strictures. There is currently no validated method or guideline in reviewing a RUG. In addition, the ability to accurately interpret RUG-derived images requires appropriate expertise and is operator-dependent [23]. It can also be more difficult to attain such professional opinions in often resource-scarce countries. Although endoscopic evaluation methods are also able to identify urethral strictures, they are not routinely utilised for cases with low suspicion, which may be considered as excessive to justify clinically [24]. In a bid to reduce inter-rater discrepancy, increase reliability, and reduce patient discomfort, Eun et al. [25] and Kim et al. [26] studied the ability to use AI and machine learning in the above 2 diagnostic modalities to improve and aid in the diagnostic process. Utilising the ResNet-50 algorithm, which is an AI technology based on convolutional

neural networks (CNNs), Eun et al. [25] trained the algorithm on 300 endoscopic videos (150 control, 150 strictures). With their deep learning technology and training, they were able to achieve encouraging results with 96.1% sensitivity with a false positive rate of 23.8% and a false negative rate of 2.9%. A high proportion of the false positive results were often in clinically ambiguous situations whereby the margins of the stricture were unclear. These results are encouraging and showcase the potential for deep learning technology to be used as an adjunct in objectively detecting strictures, limiting unnecessary resection of healthy tissue. Kim et al. [26] also utilised CNNs in a similar fashion using imaging obtained from RUG. With a training set of 242 RUG images (46 control, 196 strictures), the study team was able to report a high accuracy of 92.2% in the training set and 88.5% in their testing test, exemplifying a low amount of overfitting. These results, however, were only able to dichotomise whether a stricture was present or not, but were not able to determine the length, location, and potential aetiology, all of which are essential tenets of surgical management. Fan et al. [27] also showcased in their study that ultrasound images, when paired with Gabor wavelets, filters, and utilising back-propagation neural network algorithms, can accurately differentiate urethral lu-

men from the corpus spongiosum in normal and diseased urethras with a FPR and FNR of less than 10% and with a SI of over 90%, showing potential in the diagnostic process of urethral strictures. With the increasing application and reliable accuracy of machine learning and convolutional neural networks in diagnosing urethral strictures, there is good potential for urologists to benefit from enhanced diagnostic ability, limiting unnecessary surgical intervention.

### **Cross sectional imaging and virtual reconstruction**

In patients with traumatic urethral strictures who are unable to tolerate the position required for RUG, there is often room to consider the use of cross-sectional imaging [28, 29]. With the advent of the virtual endoscopy [30], cross-sectional imaging can be pieced together using AI to provide an endoscopic view without the invasiveness. This not only allows for increased patient comfort, but also grants physicians the ability to appreciate precise spatial relationships of pathological regions from the images generated. In addition, RUG is not a physiological examination because the forceful pressure needed to overcome the stricture when injecting the contrast may not only flatten the stricture, but also rupture the mucosal barrier, leading to a missed diagnosis and further unnecessary complications [31].

Hanna et al. [32] examined 13 patients using 4-detector row computed tomography (4-MDCT) after they were diagnosed or suspected to have urethral strictures. The contrast was inserted into the bladder by either retrograde urethral injections, suprapubic catheter injections, or standard IV route. Whilst wearing condom catheters, the patients were told to micturate in the supine or prone position whilst the CT images over 10 seconds. The images were then reconstructed on virtual endoscopy, and the final diagnosis was compared to conventional RUG or scope, with good accuracy. The utility of cross-sectional imaging also means that lesions that were initially obscured by bony structures can also be well visualised. The authors also reported a urethral stricture surrounded by dense fibrotic tissue that was diagnosed on CT and virtual endoscopy, but not on conventional RUG. Lu et al. [33] also utilised CT imaging in patients who had either suprapubic catheter or retrograde filling of the bladder. The 80 patients were filled until they had a strong urge to void, and shots were similarly taken during urination, while the MDCT images were studied as is and with virtual endoscopic fly-through navigation software. All patients then had both RUG and flexible urethroscopy within 2 days for further diagnosis. Of all the modalities utilised, MDCT

had the highest sensitivity as it picked up 51 out of 58 of the surgically diagnosed urethral strictures as compared to the 34 diagnosed on RUG and 40 diagnosed on scope. The authors show that not only does CT scanning with virtual urethroscopy take less time than conventional scopes ( $8.83 \pm 1.67$  vs  $13.55 \pm 3.67$ ,  $p < 0.001$ ), but it also correlated better with intraoperative findings as compared to RUG ( $0.964$  vs  $0.919$ ,  $p < 0.001$ ) in males.

Tsang et al. [34] studied 10 patients post high-dose-rate brachytherapy for prostate cancer in a bid to identify MRI radiomics features of the prostate gland pre-operatively that could predict post HDR BT stricture formation. They reported that the pre-procedural prostate gland had MRI radiomics features that demonstrated good ability in identifying urethral strictures post HDR BT. In analysis of the 3-dimensional grey-level co-occurrence matrix (GLCM) of these images, features such as lower contrast ( $p = 0.04$ ) and lower homogeneity ( $0.04$ ) were predictive of attaining strictures after radiotherapy. Whilst this does not showcase the diagnostic ability of MRI radiomics in urethral stricture, extracting these features from the staging MRI potentially benefits prostate cancer patients by providing an additional risk stratification for patients who are more prone to developing urethral strictures. Yekeler et al. [35] also utilised MRI scans in 18 patients with 14 strictures to assess the feasibility of contrast-enhanced MR voiding urethrography (CE 3D MRVU) with consequent virtual multiplanar assessment and virtual endoscopic reconstruction. When compared to conventional RUG, the MRI was better able to pick up severe membranous strictures (which were considered as normal on RUG) with confirmation from urethroscopy. The proximal limits of the membranous strictures were also better evaluated in CE 3D MRVU than in RUG. Additionally, patients who could not undergo traditional RUG due to the mechanical obstruction from the distal strictures were able to undergo CE 3D MRVU, obtaining an accurate diagnosis. Despite a small patient group, this study showcases the advantages of MRI with 3D virtual reconstruction over traditional methods such as RUG.

### **Novel techniques**

Cohen et al. [36, 37] studied 2 separate models and methods in identifying urethral strictures. The first was using a computational fluid dynamics (CFD) model akin to those used in cardiology [38], to assess pressure and flow parameters with different urethral stricture diseases. CFD uses complex computational and modelling techniques to analyse the

motion of fluids, estimate velocity, pressure dynamics, and flow rates. In this *in vitro* study, the authors concluded that stricture size and bladder pressure both strongly impact urinary flow, whilst stricture location, length, and sequence of multiple strictures had a weaker impact. They showed that increasing the stricture size from 15 Fr to 10 Fr decreased the mean velocity from 315.8 mm/s to 177 mm/s, and the flow from 24.8 ml/s to 13.8 ml/s. It is of note that CFD faces the same limitation as other non-invasive measurements like PVRU and uroflowmetry in the sense that it does not differentiate neurogenic bladders from a bladder outlet obstruction. Whilst their study did not account for the elasticity and shape of a true urethra, and the external compression of the prostate was also not accounted for, but their model demonstrates that flow rates from the CFD model were consistent with the uroflowmetry values found in the literature and could potentially be used as an adjunct for research and clinical practice. In a study published in 2020, Cohen et al. [36] also studied in a separate *in vitro* model the urinary spray patterns of various normal and abnormal anatomical conformations of the urethra. Despite identifying that urinary occlusion in the case of strictures leads to slow relative flow rate and could significantly increase the diameter of spray ( $p = 0.03$ ), they did not report an *in vivo* extension to diagnosing urethral strictures in humans. The findings from this study, coupled from the initial CFD study, could potentially come together to help urologists understand the confluence of dynamic flow and spray pattern in urinary diseases in identifying urethral strictures. When used as an adjunct to other investigative methods such as RUG, it could help in diagnosing and prognosticating disease burden.

## Management

### Pre-operative planning using 3D models

Urethral reconstruction is a highly intricate surgical procedure necessitating meticulous preoperative planning due to the minute and intricate anatomy of the urethra and the variability in patient presentations. The success of urethral reconstruction relies heavily on accurate and precise identification of the structured or injured segment, preservation of surrounding structures, and restoration of urethral continuity whilst avoiding periurethral injury [39]. Zhang et al. [40] showcased in their *in vitro* study that 3D-printed urethral models in the context of pelvic fracture urethral injury (PFUI) have good potential in helping clinicians plan preoperatively. The authors assessed 3 separate patients with PFUI,

and utilised 3D reconstruction software to print 3D anatomical models based on CT-attained imaging. The polycaprolactone (PCL) models took 5 hours to print on average and were evaluated subsequently with stellar results by both patients and clinicians. The former reported that when compared to other imaging modalities such as urethroscopic images or CT images, the models were easier to understand and contributed significantly to their level of disease awareness. Clinicians found that, subjectively, these models were the best in reflecting the relationship between the proximal urethra and pubic symphysis, as well as the urethra and the rectum, which are both important surgical considerations. Whilst they did opine that the models were not better in evaluating length of urethral stenosis and disease, objective measurements of disease anatomy and extent were similar between the model and intraoperative findings. Similarly, Joshi et al. [41] utilised acrylic fibres to reconstruct and print 3D printed models of 10 different patients with PFUIs. Similarly, the models were shown to help understand the anatomy of the posterior urethra, and they depicted the exact displacement of the posterior urethra, its relationship to the pubic bone anterior and the rectum posterior, its relative displacement from the midline, and the status of the anterior urethral wall. Field experts such as practising urologists and fellows subjectively reported that these models were useful in helping them make peri- and pre-operative assessments, especially with regards to the need to perform an inferior pubectomy to bridge the gap between the 2 ends of the urethra. Utilising these models to plan preoperatively has also been reported to shorten surgical time. The status and accuracy of 3D models printed using CT-attained imaging gives an insight into the potential use of 3D models for preoperative planning as well as patient disease education.

### Bioengineering urethral tissues

Accurate diagnosis and good pre-operative planning, as previously mentioned, are all important cornerstones in the journey of the patient with a urethral stricture. The successful outcome of the patient thereafter lies in the hands of a good surgical repair alongside adequate urethral reconstruction. The latter often is done by utilising substitute materials such as an autologous penile flap or mucosa from the buccal [42–44], which often come at the expense of significant risk of damage or true damage to the donor site, such as, but not limited to, bleeding, infection, nervous injury, cosmetic injury, and even functional limitations. Hence, there has been a rapid development in the utilisation of tissue bioengineer-

ing and regenerative medicine as an alternative approach. In the realm of 3D-based applications, Zhang et al. [45] showed that 3D bioprinting technology using CT-obtained images can fabricate urethras *in vitro* using PCL and polylactide-co-caprolactone (PLCL) polymers in a spiral scaffold design to mimic the structural and mechanical properties of urethras in rabbits. The authors also showed that cell-laden fibrin-based hydrogels, when used on the 50/50 PLCL polymers in a spiral design, had a highly suitable and optimal microenvironment for bladder cells and smooth muscle cells to be viable, to proliferate and to express cell-specific biomarkers overtime, allowing for potential future expansion into human use. Huang et al. [46] also showed that urethral reconstruction using a novel 3D porous bacterial cellulose scaffold seeded with rabbit lingual keratinocyte had good potential when compared to other techniques in formulating urethras that maintained their inner calibres without reforming strictures over time. Collagen-based tubular scaffolds, when used in the context of urethral bioengineering, have also been shown to have sufficient intrinsic radial elasticity that is potentially useful in the regeneration of dynamic tubular organs such as the urethra [47], with the potential to remain functional for at least 6 years in the clinical setting [48].

## DISCUSSION

### Diagnosics

Urethral stricture disease presents a significant challenge in the field of urology, affecting patients' quality of life as well as potentially leading to severe complications if left untreated. Traditional diagnostic modalities such as RUG and urethroscopy, whilst effective, have limitations including operator dependency, invasiveness, and the potential for missing or misdiagnosing strictures. However, recent advancements in AI, machine learning, radiomics, and imaging technologies, as discussed above, offer promising solutions to enhancing diagnostic accuracy and patient outcomes. The integration of AI and machine learning algorithms into diagnostic processes has already shown encouraging results in improving the interpretation and accuracy of imaging modalities such as RUG and ultrasound. With deep learning algorithms already shown to reduce operator dependence and inter-rater variability in other fields [49, 50], urologists can also benefit greatly from these in the field of strictures. A paradigm shift towards more objective and reliable diagnostic methods can ultimately benefit patients by minimising unnecessary interventions and by optimising treatment planning.

Furthermore, cross-sectional imaging techniques when combined with virtual reconstruction can offer non-invasive alternatives to traditional diagnostic procedures, especially with patients who may not tolerate invasive techniques or those with complex anatomical and surgical considerations. With early studies showing keen progress in the utility of CT imaging and virtual endoscopy in visualising urethral strictures when compared to traditional and conventional RUG, patients can potentially benefit in the long run by reducing unnecessary exposure to sedation risks and procedural risks. Additionally, the ability of MRI radiomics and features on early cross-sectional imaging to provide valuable insights into predicting post-therapeutic outcomes and assessing the severity of strictures allows clinicians to better stratify and counsel patients on their potential outcomes.

### Management

Education via models, ranging from standard silicone models, custom printed metal implants, and even 3D-printed replicas, have been shown in various fields to improve patient education and satisfaction [51–53]. In addition, 3D modelling techniques have also been shown to offer invaluable tools for perioperative surgical planning and assessment, especially in regard to anatomically challenging and non-standard cases [54–58]. Studies by Zhang et al. [40] and Joshi et al. [41] showcased the efficacy of 3D-printed models in facilitating surgical planning in the setting of urethral strictures, as above. Further cohort-based prospective studies can help us gain better insight into the extent of benefits in both patient and surgical outcomes of these printed models.

The emergence of bioengineering and regenerative medicine also presents promising avenues for tissue reconstruction in the realm of urethral strictures. The ability to create patient-specific biomimetic tissue constructs that closely resemble native tissue architecture and function holds great promise because it allows for tailored interventions that address individual patient's needs and minor anatomical variations [59]. Additionally, the potential for enhanced biocompatibility means reduced immunogenicity and improved interaction with host tissues as compared to traditional graft materials. The ability to minimise donor site morbidity and eliminate the need for secondary surgical procedures to obtain or fix these grafts are also of great benefit to patients. In orthopaedics, 3D-printed implants and scaffolds have already been used to regenerate bony tissue in patients with bone defects and fractures [60–62]. Similarly, tissue-engineered heart valves and patches have shown great results in restoring cardiac function

and fixing valvular abnormalities in the realm of cardiothoracic surgery [63–65]. The integration of bioengineering and regenerative medicine principles holds tremendous potential in revolutionising the field of stricture management, offering innovative solutions that improve outcomes whilst reducing risks for this debilitating condition. Further research is required to optimise tissue engineering techniques, validate their efficacy in clinical trials, and ensure their safe implementation into routine urological practice.

### Current limitations and future directions

The implementation of advanced technologies such as artificial intelligence, machine learning, radiomics, and 3D printing may face significant challenges related to cost, infrastructure, and expertise, particularly in resource-limited settings across the world. Future studies should include centre-based cost analyses to assess suitability. Additionally, the included studies primarily focused on specific aspects of urethral stricture management and diagnosis but did not report certain important aspects such as patient-reported outcomes and cost effectiveness. Most of the studies were also observational retrospective studies or experimental in nature, which lacks robust clinical validation in diverse patient populations. Future research should hence aim to address these gaps with more comprehensive reviews and randomised controlled trials. Large-scale, multicentre studies are needed

to validate the efficacy, safety, and cost-effectiveness of these novel technologies and interventions. It is envisioned that with further development and availability of these advanced technologies, urethral strictures will be a condition that is readily diagnosed and managed with optimal patient outcomes and prognosis.

### CONCLUSIONS

Our scoping review underscores the transformative potential of innovative technologies in advancing the diagnosis and management of urethral strictures. Recent advancements in AI, machine learning, 3D printing, and radiomics offer promising avenues for enhancing diagnostic accuracy and reliability over traditional methods. Cross-sectional imaging techniques, when coupled with virtual reconstruction, also provide non-invasive alternatives whilst providing prognosticating insights. Additionally, 3D printing and bioengineering approaches hold promise for personalised interventions with reduced site morbidity.

### CONFLICTS OF INTEREST

The authors declare no conflict of interest.

### FUNDING

This research received no external funding.

### ETHICS APPROVAL STATEMENT

Approval of the Bioethics Committee was not required.

### References

1. Tritschler S, Roosen A, Füllhase C, Stief CG, Rübber H. Urethral stricture: etiology, investigation and treatments. *Dtsch Arztebl Int.* 2013; 110: 220-226.
2. Lubahn JD, Zhao LC, Scott JF, et al. Poor quality of life in patients with urethral stricture treated with intermittent self-dilation. *J Urol.* 2014; 191: 143-147.
3. King C, Rourke KF. Urethral Stricture is Frequently a Morbid Condition: Incidence and Factors Associated With Complications Related to Urethral Stricture. *Urology.* 2019; 132: 189-194.
4. Stein DM, Thum DJ, Barbagli G, et al. A geographic analysis of male urethral stricture aetiology and location. *BJU Int.* 2013; 112: 830-834.
5. Maciejewski C, Rourke K. Imaging of urethral stricture disease. *Transl Androl Urol.* 2015; 4: 2-9.
6. Frankiewicz M, Markiet K, Kozak O, et al. Retrograde urethrography, sonourethrography and magnetic resonance urethrography in evaluation of male urethral strictures. Should the novel methods become the new standard in radiological diagnosis of urethral stricture disease? *Int Urol Nephrol.* 2021; 53: 2423-2435.
7. Mahmud SM, El KS, Rana AM, Zaidi Z. Is ascending urethrogram mandatory for all urethral strictures? *J Pak Med Assoc.* 2008; 58: 429-431.
8. Goel A, Gupta A, Dalela D. Antegrade urethrogram: A technique to visualize the proximal bulbous urethral segment in anterior urethral stricture. *Indian J Urol.* 2009; 25: 415-416.
9. Resident, Department of Radio-Diagnosis, National Institute of Medical Science and Research, Jaipur, Rajasthan, INDIA., Labana S, Bansal RP, Professor and HOD, Department of Radio-Diagnosis, National Institute of Medical Science and Research, Jaipur, Rajasthan, INDIA. Role of MR urethrography in detection and characterization of various urethral lesions in male patients and its comparison with conventional urethrography and Sonourethrography. *MIJRAD.* 2020; 13: 114-117.
10. Hampson LA, McAninch JW, Breyer BN. Male urethral strictures and their management. *Nat Rev Urol.* 2014; 11: 43-50.
11. Bhowmik P, Sharma G, Sharma PK, Patwari PK, Dey S, Mandal S. Prospective study of de novo sexual dysfunction after anterior urethroplasty: Causative factors, incidence, and recovery of function – A single-center experience. *Urol Ann.* 2022; 14: 60-66.
12. Al-Qudah HS, Santucci RA. Extended complications of urethroplasty. *Int Braz J Urol.* 2005; 31: 315-323.



13. Bouhadana D, Lu XH, Luo JW, et al. Clinical Applications of Machine Learning for Urolithiasis and Benign Prostatic Hyperplasia: A Systematic Review. *J Endourol.* 2023; 37: 474-494.
14. Lim EJ, Yen J, Fong KY, et al. Radiomics in Kidney Transplantation: A Scoping Review of Current Applications, Limitations, and Future Directions. *Transplantation.* 2024; 108: 643-653.
15. Lim EJ, Castellani D, So WZ, et al. Radiomics in Urolithiasis: Systematic Review of Current Applications, Limitations, and Future Directions. *J Clin Med.* 2022; 11: 5151.
16. Ahsan MM, Luna SA, Siddique Z. Machine-Learning-Based Disease Diagnosis: A Comprehensive Review. *Healthcare (Basel).* 2022; 10: 541.
17. Takebayashi S, Hosaka M, Kubota Y, et al. Computerized tomographic ureteroscopy for diagnosing ureteral tumors. *J Urol.* 2000; 163: 42-46.
18. Checcucci E, Piazza P, Micali S, et al. Three-dimensional Model Reconstruction: The Need for Standardization to Drive Tailored Surgery. *Eur Urol.* 2022; 81: 129-131.
19. Piramide F, Kowalewski KF, Cacciamani G, et al. Three-dimensional Model-assisted Minimally Invasive Partial Nephrectomy: A Systematic Review with Meta-analysis of Comparative Studies. *Eur Urol Oncol.* 2022; 5: 640-650.
20. Meyer-Szary J, Luis MS, Mikulski S, et al. The Role of 3D Printing in Planning Complex Medical Procedures and Training of Medical Professionals—Cross-Sectional Multispecialty Review. *Int J Environ Res Public Health.* 2022; 19: 3331.
21. Atala A, Bauer SB, Soker S, Yoo JJ, Retik AB. Tissue-engineered autologous bladders for patients needing cystoplasty. *Lancet.* 2006; 367: 1241-1246.
22. McCallum RW, Colapinto V. The role of urethrography in urethral disease. Part I. Accurate radiological localization of the membranous urethra and distal sphincters in normal male subjects. *J Urol.* 1979; 122: 607-611.
23. Bach P, Rourke K. Independently interpreted retrograde urethrography does not accurately diagnose and stage anterior urethral stricture: the importance of urologist-performed urethrography. *Urology.* 2014; 83: 1190-1193.
24. Shahrour W, Joshi P, Hunter CB, et al. The Benefits of Using a Small Caliber Ureteroscope in Evaluation and Management of Urethral Stricture. *Adv Urol.* 2018; 2018: 9137892.
25. Eun SJ, Park JM, Kim KH. Development of an Artificial Intelligence-Based Support Technology for Urethral and Ureteral Stricture Surgery. *Int Neurourol J.* 2022; 26: 78-84.
26. Kim JK, McCammon K, Robey C, et al. Identifying urethral strictures using machine learning: a proof-of-concept evaluation of convolutional neural network model. *World J Urol.* 2022; 40: 3107-3111.
27. Fan H, Chen L, Feng C, Li Z, Zhao Y, Zhang S. Segmentation of corpus spongiosum from male anterior urethra ultrasound images. In: 2017 International Conference on Wavelet Analysis and Pattern Recognition (ICWAPR) [Internet]. Ningbo, China: IEEE; 2017 [cited 2024 Feb 21]. pp. 159-165. Available from: <http://ieeexplore.ieee.org/document/8076682/> (Access: 21.02.2024).
28. Osman Y, El-Ghar MA, Mansour O, Refaie H, El-Diasty T. Magnetic resonance urethrography in comparison to retrograde urethrography in diagnosis of male urethral strictures: is it clinically relevant? *Eur Urol.* 2006; 50: 587-593.
29. El-Kassaby AW, Osman T, Abdel-Aal A, Sadek M, Nayef N. Dynamic three-dimensional spiral computed tomographic cysto-urethrography: a novel technique for evaluating post-traumatic posterior urethral defects. *BJU Int.* 2003; 92: 993-996.
30. Kagadis GC, Siablis D, Liatsikos EN, Petsas T, Nikipforidis GC. Virtual endoscopy of the urinary tract. *Asian J Androl.* 2006; 8: 31-38.
31. Mullin EM, Peterson LJ, Paulson DF. Retrograde urethrogram: diagnostic aid and hazard. *J Urol.* 1973; 110: 462-466.
32. Hanna SAZ, Abd El-Rahman SF, Barsoum NR, El Gammal MY. Role of MDCT in evaluation of urethral lesions. *Egypt J Radiol Nucl Med.* 2011; 42: 249-255.
33. Lv XG, Peng XF, Feng C, Xu YM, Shen YL. The application of CT voiding urethrography in the evaluation of urethral stricture associated with fistula: a preliminary report. *Int Urol Nephrol.* 2016; 48: 1267-1273.
34. Tsang YM, Vignarajah D, McWilliam A, et al. A pilot study on dosimetric and radiomics analysis of urethral strictures following HDR brachytherapy as monotherapy for localized prostate cancer. *Br J Radiol.* 2020; 93: 20190760.
35. Yekeler E, Suleyman E, Tunaci A, et al. Contrast-enhanced 3D MR voiding urethrography: preliminary results. *Magn Reson Imaging.* 2004; 22: 1193-1199.
36. Cohen AJ, Patino G, Mirramezani M, et al. Novel measurement tool and model for aberrant urinary stream in 3D printed urethras derived from human tissue. *PLoS One.* 2020; 15: e0241507.
37. Cohen AJ, Baradaran N, Mena J, Krsmanovich D, Breyer BN. Computational Fluid Dynamic Modeling of Urethral Strictures. *J Urol.* 2019; 202: 347-353.
38. Morris PD, Narracott A, von Tengg-Kobligk H, et al. Computational fluid dynamics modelling in cardiovascular medicine. *Heart.* 2016; 102:18-28.
39. Erickson BA, Ghareeb GM. Definition of Successful Treatment and Optimal Follow-up after Urethral Reconstruction for Urethral Stricture Disease. *Urol Clin North Am.* 2017; 44: 1-9.
40. Zhang K, Liu J, Wang L, Li W, Qi E, Fu Q. Application of 3D printed pelvic fracture related urethra and surrounding tissue as preoperative planning model. *BMC Urol.* 2023; 23: 1.
41. Joshi PM, Kulkarni SB. 3D printing of pelvic fracture urethral injuries-fusion of technology and urethroplasty. *Turk J Urol.* 2019; 46: 76-79.
42. Hmida W, Othmen MB, Bako A, Jaidane M, Mosbah F. Penile skin flap: a versatile substitute for anterior urethral stricture. *Int Braz J Urol.* 45: 1057-1063.
43. Shaw NM, Amend G, Breyer BN. Genital flaps for anterior urethral reconstruction. *Plast Aesthet Res.* 2021; 8: 52.
44. Selim M, Salem S, Elsherif E, Badawy A, Elshazly M, Gawish M. Outcome of staged buccal mucosal graft for repair of long segment anterior urethral stricture. *BMC Urol.* 2019; 19: 38.
45. Zhang K, Fu Q, Yoo J, et al. 3D bioprinting of urethra with PCL/PLCL blend and dual autologous cells in fibrin hydrogel:

- An in vitro evaluation of biomimetic mechanical property and cell growth environment. *Acta Biomaterialia*. 2017; 50: 154-164.
46. Huang JW, Lv XG, Li Z, et al. Urethral reconstruction with a 3D porous bacterial cellulose scaffold seeded with lingual keratinocytes in a rabbit model. *Biomed Mater*. 2015; 10: 055005.
47. Versteegden LR, Van Kampen KA, Janke HP, et al. Tubular collagen scaffolds with radial elasticity for hollow organ regeneration. *Acta Biomaterialia*. 2017; 52: 1-8.
48. Raya-Rivera A, Esquiliano DR, Yoo JJ, Lopez-Bayghen E, Soker S, Atala A. Tissue-engineered autologous urethras for patients who need reconstruction: an observational study. *Lancet*. 2011; 377: 1175-1182.
49. De Rosa L, L'Abbate S, Kusmic C, Faita F. Applications of Deep Learning Algorithms to Ultrasound Imaging Analysis in Preclinical Studies on In Vivo Animals. *Life (Basel)*. 2023; 13: 1759.
50. Liu S, Wang Y, Yang X, et al. Deep Learning in Medical Ultrasound Analysis: A Review. *Engineering*. 2019; 5: 261-275.
51. Zhuang YD, Zhou MC, Liu SC, Wu JF, Wang R, Chen CM. Effectiveness of personalized 3D printed models for patient education in degenerative lumbar disease. *Patient Educ Couns*. 2019; 102: 1875-1881.
52. Wake N, Rosenkrantz AB, Huang R, et al. Patient-specific 3D printed and augmented reality kidney and prostate cancer models: impact on patient education. *3D Print Med*. 2019; 5: 4.
53. Traynor G, Shearn AI, Milano EG, et al. The use of 3D-printed models in patient communication: a scoping review. *J 3D Print Med*. 2022; 6: 13-23.
54. Segaran N, Saini G, Mayer JL, et al. Application of 3D Printing in Preoperative Planning. *J Clin Med*. 2021; 10: 917.
55. Schlegel L, Ho M, Fields JM, Backlund E, Pugliese R, Shine KM. Standardizing evaluation of patient-specific 3D printed models in surgical planning: development of a cross-disciplinary survey tool for physician and trainee feedback. *BMC Medical Education*. 2022; 22: 614.
56. Boedecker C, Huettl F, Saalfeld P, et al. Using virtual 3D-models in surgical planning: workflow of an immersive virtual reality application in liver surgery. *Langenbecks Arch Surg*. 2021; 406: 911-915.
57. Fadero PE, Shah M. Three dimensional (3D) modelling and surgical planning in trauma and orthopaedics. *Surgeon*. 2014; 12: 328-333.
58. Bianchi L, Cercenelli L, Bortolani B, et al. 3D renal model for surgical planning of partial nephrectomy: A way to improve surgical outcomes. *Front Oncol*. 2022; 12: 1046505.
59. Shopova D, Yaneva A, Bakova D, et al. (Bio)printing in Personalized Medicine – Opportunities and Potential Benefits. *Bioengineering (Basel)*. 2023; 10: 287.
60. Fang C, Cai L, Chu G, Jarayabhand R, Kim JW, O'Neill G. 3D printing in fracture treatment. *Unfallchirurgie*. 2022; 125: 1-7.
61. Meng M, Wang J, Huang H, Liu X, Zhang J, Li Z. 3D printing metal implants in orthopedic surgery: Methods, applications and future prospects. *J Orthop Translat*. 2023; 42: 94-112.
62. Lal H, Patralekh MK. 3D printing and its applications in orthopaedic trauma: A technological marvel. *J Clin Orthop Trauma*. 2018; 9: 260-268.
63. Noor N, Shapira A, Edri R, Gal I, Wertheim L, Dvir T. 3D Printing of Personalized Thick and Perfusible Cardiac Patches and Hearts. *Adv Sci (Weinh)*. 2019; 6: 1900344.
64. Asulin M, Michael I, Shapira A, Dvir T. One-Step 3D Printing of Heart Patches with Built-In Electronics for Performance Regulation. *Adv Sci (Weinh)*. 2021; 8: 2004205.
65. Bhandari S, Yadav V, Ishaq A, et al. Trends and Challenges in the Development of 3D-Printed Heart Valves and Other Cardiac Implants: A Review of Current Advances. *Cureus*. 2023; 15: e43204. ■