

# Visual clarity of irrigants used during flexible ureterorenoscopy: an in vitro comparison

Volkan Ulker<sup>1</sup>, Zeki Gulerce<sup>2</sup>, Orcun Celik<sup>1</sup>, Ozgur Cakmak<sup>1</sup>, Cem Yucel<sup>1</sup>, Ertan Can<sup>1</sup>, Burak Turna<sup>3</sup>

<sup>1</sup>Health Sciences University Tepecik Training and Research Hospital, Department of Urology, Izmir, Turkey

<sup>2</sup>Bornova Turkan Ozilhan State Hospital, Department of Urology, Izmir, Turkey

<sup>3</sup>Ege University Medical School, Department of Urology, Izmir, Turkey

**Citation:** Ulker V, Gulerce Z, Celik O, et al. Visual clarity of irrigants used during flexible ureterorenoscopy: an in vitro comparison. Cent European J Urol. 2020; 73: 514-519.

## Article history

Submitted: Sept. 2, 2020

Accepted: Oct. 21, 2020

Published online: Nov. 9, 2020

## Corresponding author

Volkan Ulker  
Tepecik Training  
and Research Hospital  
Department of Urology  
1140/1 s. No: 1 Yenisehir  
35180 Izmir, Turkey  
phone: +90 532 432 47 63  
ulkerv@hotmail.com

**Introduction** Saline solution is the standard irrigant used during ureteroscopy. However, there is an opinion that water has better visual clarity. We aimed to compare the visual clarities of saline, water, and 5% mannitol as an irrigant during ureteroscopy.

**Material and methods** An in vitro model consisting of an irrigant-filled container and a fiberoptic flexible ureteroscope was designed. A 1951 USAF Resolution Test Target and color checker within irrigants were used to evaluate the clarity of vision. The visual clarity was compared for 0.9% saline, distilled water and 5% mannitol solution with screen resolution and color contrast. The tests were repeated after adding human blood (2/400 ml) and contrast (20/400 ml) to the irrigants.

**Results** There was no significant difference in resolution values of three plain irrigants at a distance of 10 mm. However, when blood was added to the irrigants, a better resolution of 29.3% for water and 20.6% for mannitol was achieved compared to saline. At 20 mm of distance, it was observed that the difference was more pronounced in irrigants with blood. Water and mannitol had 55.6% and 37.1% better resolution than saline, respectively. In the color reproduction test, there was no significant difference in the three plain irrigants, however, water had better color contrast compared to the others.

**Conclusions** Water and 5% mannitol did not provide a significant image clarity advantage compared to saline. However, when blood was added to the irrigants, water provided significantly better visual clarity compared to saline. The use of water during various clinical scenarios in flexible ureteroscopy should be further investigated.

**Key Words:** ureteroscopy ◊ flexible ureteroscope ◊ saline solution ◊ sterile water ◊ quality

## INTRODUCTION

The application of flexible ureterorenoscopy in urology was first described by Marshall in 1964 [1]. Today, flexible ureterorenoscopy (URS) is an integral part of modern urological practice. With advances in ureteroscope design and laser technology, the indications of flexible URS and retrograde intrarenal surgery (RIRS) have expanded in the minimally invasive surgery of the upper urinary tract pathologies, specifically for urinary stones and upper urothelial tumors. Although the use of digital ureteroscopes

with superior image quality is increasing, fiberoptic ureteroscopes with a lower image quality are still widely used. However, obtaining optimal image quality is quite important during RIRS with fiberoptic devices, since suboptimal image quality may interfere with the efficacy of the procedure [2].

The other determinant of image clarity in URS is the irrigant used. Isotonic saline is used as a standard irrigant during flexible URS and RIRS to prevent hyponatremia and hemolysis due to hypotonic fluid absorption and transurethral resection (TUR) syndrome [3]. American Urological Association (AUA)

guidelines on urinary stone disease also strongly recommend the use of isotonic saline in URS [4]. On the other hand, sterile water may provide a better visibility for URS and lysis red blood cells which allows improved light emission and clarity.

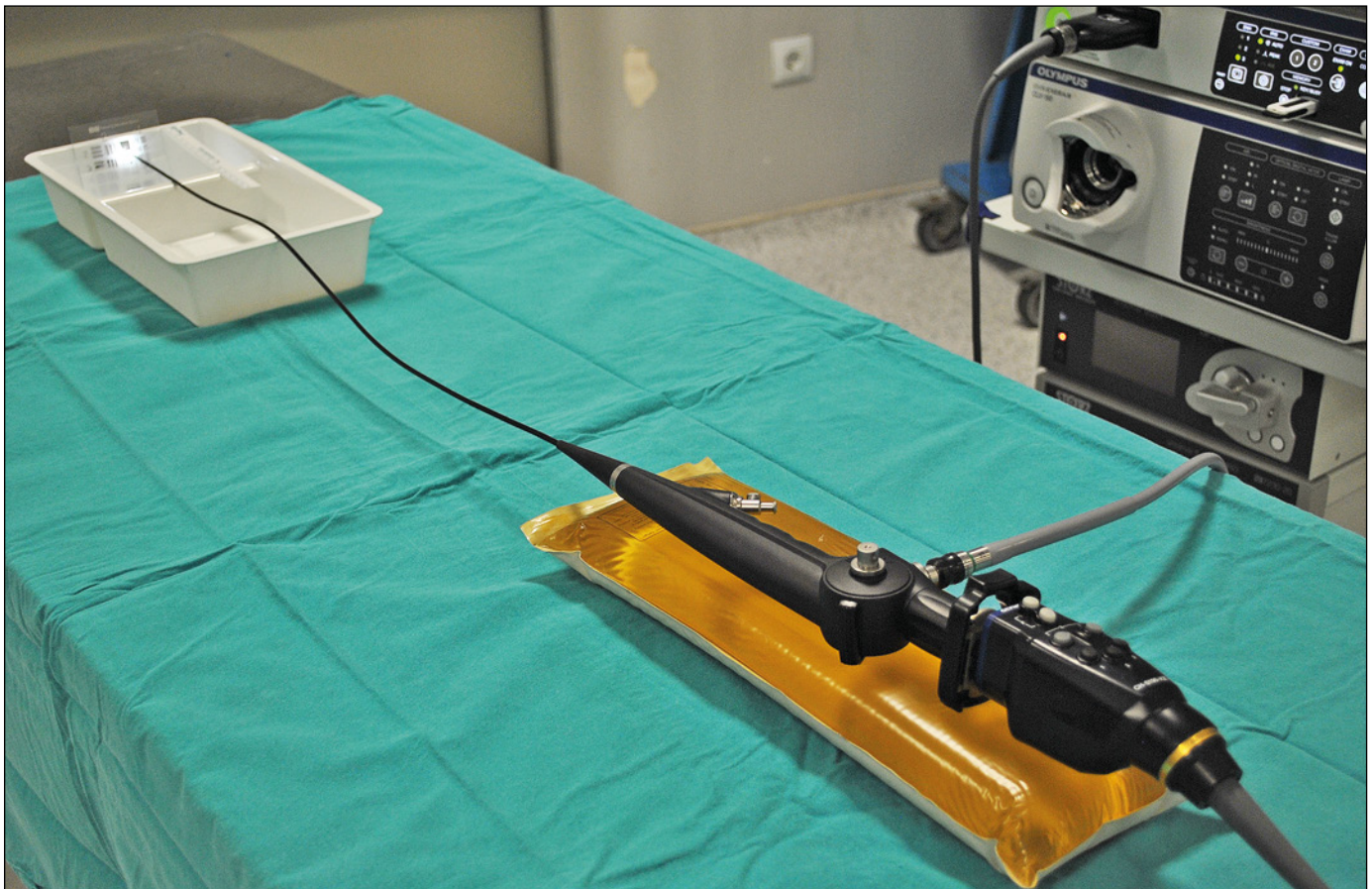
There are very limited studies that compare isotonic saline and sterile water in terms of visual clarity in endoscopy. In this in vitro study, we aimed to compare the visual clarity of isotonic saline, distilled water, and additionally 5% mannitol as irrigants for URS.

## MATERIAL AND METHODS

We designed an in vitro model consisting of an irrigant-filled container and a fiberoptic flexible ureteroscope. The test environment was prepared by a technician then observers evaluated it blindly. A resolution test target and a color checker placed in an irrigant-filled container were used to evaluate the clarity of vision (Figure 1). The fiberoptic ureteroscope visualized the resolution test target and a color checker at an angle of 90 degrees. Using

screen resolution and color contrast, the visual clarities were compared for 0.9% isotonic saline, sterile distilled water and 5% mannitol solution. Each 400 ml of irrigant was assessed in three versions; plain, with 2 ml of human blood added (from VU) to simulate slight bleeding during URS, and with 20 ml of contrast added. A brand new flexible fiberoptic ureteroscope (The Viper, Richard Wolf, Knittlingen, Germany) and a high definition (HD) camera system (Evis Exera III CV-190, Olympus, Tokyo, Japan) with a xenon light source (CLV-S190, Olympus, Tokyo, Japan) were used during the tests. Images were viewed on 1920x1080 pixels, 26 inch, HD color display (FSN Medical Technologies, Anaheim, CA, USA).

Screen resolution was determined by viewing a 1951 USAF 3x3 inch, positive Resolution Target (stock# 36-275, Edmund Optics, Barrington, NJ, USA) at a distance of 10 and 20 mm (Figure 2). Resolution was recorded in line pairs per millimeter (line pairs/mm) using a reference chart attached to the test target (Table 1). A 1951 USAF Resolution Target consists of horizontal and vertical bars organized



**Figure 1.** In vitro model consisting of a 1951 USAF resolution test target in an irrigant-filled container and a Wolf fiberoptic flexible ureteroscope.



**Table 1.** Resolution values for USAF 1951 Test Target (line pairs per mm)

Element	Group number											
	-2	-1	0	1	2	3	4	5	6	7	8	9
1	.250	.500	1.00	2.00	4.00	8.00	16.0	32.0	64.0	128	256	512
2	.280	.561	1.12	2.24	4.49	8.98	18.0	36.0	71.8	144	287	575
3	.315	.630	1.26	2.52	5.04	10.1	20.2	40.3	80.6	161	323	645
4	.353	.707	1.41	2.83	5.66	11.3	22.6	45.3	90.5	181	362	–
5	.397	.793	1.59	3.17	6.35	12.7	25.4	50.8	102	203	406	–
6	.445	.891	1.78	3.56	7.13	14.3	28.5	57.0	114	228	456	–

in groups and elements. Each group is comprised of up to nine elements within a range of twelve groups. Every element is composed of three horizontal and three vertical bars equally spaced with one another within a group and corresponds to an associated resolution based on bar width and space. The vertical bars are used to calculate horizontal resolution and horizontal bars are used to calculate vertical resolution. Resolution is defined as the highest group and elements in which the three bars can still be distinguished. All test were performed twice by three urologists.

Color representation was evaluated with a Gretag-Macbeth color checker 5.7x8.25 cm (ColorChecker Classic Mini, X-Rite Inc, Grand Rapids, MI, USA) for red. Two observers (VU and ZG) graded the color representation from 0 to 2 (0 – no similarity; 1 – little similarity; 2 – great similarity). Gretag-Macbeth is a test pattern scientifically designed to help determine the true color balance or optical density of any color rendition system. It is an industrial standard that provides a non-subjective comparison with a ‘test pattern’ of 24 scientifically prepared colored squares. Each color square represents a natu-


**Table 2.** Resolution (line pairs/mm) values of irrigants at a distance of 10 mm

	Saline	Water	5% mannitol
Plain	2.83	3.17	3.17
Blood added	1.78	2.52	2.24
Contrast added	2.52	2.83	2.83


ral object providing a qualitative maintaining color reference to countable values (Figure 3). The color representation test was performed for all three variants of each irrigant at a distance of 10 and 20 mm.

RESULTS

Table 2 shows the resolution values at a distance of 10 mm. There was no significant difference in resolution values of the three plain irrigants at a distance of 10 mm. Values of distilled water and 5% mannitol were only slightly better than isotonic saline. Similarly, when contrast was added to the irrigants, there was no significant difference.



**Figure 2.** A. 1951 USAF Resolution Test Target. Middle: resolution in the sterile water at 20 mm using 1951 USAF Resolution Test Target. B. Resolution in the saline with blood at 10 mm.



**Figure 3.** A. Gretag-Macbeth X-rite Color Checker. B. Color contrast in the saline at 20 mm.

**Table 3.** Resolution (line pairs/mm) values of irrigants at a distance of 20 mm

	Saline	Water	5% mannitol
Plain	1.12	1.78	1.26
Blood added	0.56	1.26	0.89
Contrast added	1.12	1.59	1.26

However, when blood was added to the irrigants, 29.3% for water and 20.6% for 5% mannitol better resolution values were obtained than saline.

As shown in Table 3, when the measuring distance was increased to 20 mm for the plain irrigants, distilled water had a slightly better resolution value than 5% mannitol and isotonic saline, while 5% mannitol solution had a higher resolution value than isotonic saline. Similar values were obtained for the three irrigants when contrast was added to the fluids. Moreover, it was observed that the difference was more pronounced in irrigants with blood at a 20 mm distance. At this distance, water and mannitol had 55.6% and 37.1% better resolution than saline, respectively.

In the color reproduction test, there was no difference between the three plain irrigants. The addition of contrast to the irrigants also did not cause a significant change. However, when blood was added to the irrigants, distilled water had better color contrast compared to the others and this situation did not change at distances of 10 and 20 mm.

## DISCUSSION

Sterile water is considered to provide a clearer visual field in URS. However, data is scarce and suffi-

cient studies have not been published on this subject. In their study which was presented during a congress, Huen et al. compared sterile water with isotonic saline. Serum sodium and osmolarity were assessed before and after the ureteroscopic procedures. Fluid clarity was also evaluated using spectroscopy. The authors concluded that sterile water as an irrigant did not cause clinically significant changes in serum sodium and osmolarity after URS but sterile water appeared to give clearer endoscopic visualization [5]. Similarly, in a prospective, randomized and double-blinded study from the same institution, Pirani et al. compared the visual clarity of sterile water with isotonic saline by subjective surgeon scores and turbidimeter analysis during URS. In this study, the authors used turbidimeter to measure fluid cloudiness in samples obtained from the renal pelvis and concluded that using sterile water is safe during URS, in addition to its visual superiority to isotonic saline [6]. Although turbidimetry objectively measures the particle rate of the water, alone it is not a sufficient method for comparing image clarity for URS. In our study, we preferred resolution measurement instead of subjective surgeon scoring. Talso et al. compared vision qualities of different flexible ureteroscopes with different irrigants using a 1951 USAF resolution test target in vitro [7]. Color contrast was also evaluated with a color checker. In this study, no significant difference appeared in the resolution values of sterile water and isotonic saline. However, they used iodine solution in order to simulate bleeding as opposed to real blood as in our study. In our study, we also tried to compare the visual clarities of distilled water and isotonic saline using a 1951 USAF resolution test target and found that at a distance of 10 mm, resolution

in distilled water was comparable with isotonic saline while at a distance of 20 mm, distilled water was slightly superior.

The main concern regarding the use of sterile water during RIRS is the possibility that water can pass into systemic circulation by pyelovenous and pyelolymphatic absorption and cause TUR syndrome. TUR syndrome is characterized by systemic fluid overload and dilutional hyponatremia that is seen in a variety of endoscopic surgical procedures, although classically after transurethral resection of the prostate (TURP) [8]. Depending on the amount of fluid absorbed, the clinical picture of TUR syndrome may change from asymptomatic hyponatremia to confusion, coma and death [9]. Additionally, the sterile water used as irrigation fluid can cause intravascular hemolysis when absorbed. TUR syndrome has also been reported after some endoscopic procedures such as TUR of bladder tumors [10], percutaneous nephrolithotomy (PCNL) [11, 12] diagnostic cystoscopy [13], arthroscopy [14] and transcervical resection of the endometrium (TCRE) [15] in which irrigation fluid was used. Several methods have been used to measure the amount of absorbed irrigant during endoscopic surgery. Cybulski et al. investigated the amount of fluid absorbed during URS in a prospective study [16]. They performed a volumetric fluid balance and concluded that routine URS is associated with minimal systemic fluid absorption and sterile water for URS is safe even if ureteral perforation occurs. Conversely, in a prospective study which ethanol 1% was used as irrigant, it has been showed that absorbed fluid during RIRS was not negligible [17]. Zeltser et al. stated in their commentary that even though sterile water has better visibility, isotonic saline should be the irrigant of choice in ureterorenoscopic procedures since sterile water may cause serious complications including cardiovascular collapse, in accordance to their personal observations [18]. On the other hand, it is known that the ureteral access sheath use can decrease the amount of absorbed fluid. Since the sterile water used for irrigation may cause intravascular hemolysis, non-electrolyte solutions containing glycine, sorbitol and mannitol have been introduced to prevent hemolysis. In this manner, we decided to use 5% mannitol in addition to distilled water and isotonic saline during the tests to see its clarity of vision in URS.

Sterile water as a hypotonic fluid causes lysis of red blood cells and improves visibility during

URS if bleeding exists. In our study, when blood was added to irrigation fluids, a significantly better visual field was obtained with distilled water compared to isotonic saline at a distance of 10 and 20 mm. Although the visual advantage of sterile water can be negligible in the use of digital ureteroscopes which have higher resolution, it can be argued that sterile water can provide a better image in case of bleeding when using fiberoptic ureteroscopes. Additionally, color representation was better in water when blood was added. However, we could not observe any visual superiority of distilled water compared to isotonic saline when contrast was added to the irrigants. In this context, we advocate the use of small amounts of sterile water during flexible URS in the clinical setting.

Our study has some limitations. The main limitation is being of an *in vitro* nature. Since we performed tests within static fluids, continuous fluid circulation in clinical applications may lead to different results. More advanced techniques are available to measure image resolution. However, we preferred the 1951 USAF Test Target as it was easy to use and was used as a standard in previous studies. For this reason, statistical evaluation could not be made due to the low number of variables and the resolution values to be read from their own table. Although the use of a resolution test target for evaluation of visual clarity gives a numerical value, it should be kept in mind that it is also subjective and there may be a bias. Finally, the subjective nature of color reproduction evaluation and low number of observers limit the study.

## CONCLUSIONS

Our *in vitro* study showed that the use of sterile distilled water and mannitol 5% instead of isotonic saline during URS with a fiberoptic scope did not provide a significant image clarity advantage. However, when blood was added to the irrigation fluids, distilled water provided significantly better visual clarity compared to isotonic saline. In cases of potential bleeding and image quality deterioration such as impacted stones or upper urinary tract tumors, the use of sterile water as an irrigant in flexible URS should be further investigated, especially when a fiberoptic scope is used.

## CONFLICTS OF INTEREST

The authors declare no conflicts of interest.



## References

1. Marshall VF. Fiber optics in urology. *J Urol.* 1964; 91: 110-114.
2. Scoffone CM, Cracco CM, Poggio M, Cossu M, Scarpa RM. Treatment of the pyelocalyceal tumors with laser. *Arch Esp Urol.* 2008; 61: 1080-1087.
3. Hahn RG. Fluid absorbtion in endoscopic surgery. *Br J Anaesth.* 2006; 96: 8-20.
4. Assimos D, Krambeck A, Miller NL, et al. Surgical Management of Stones: American Urological Association/Endourological Society guideline, PART I. *J Urol.* 2016; 196: 1153-1160.
5. Huen KH, Bui DT, Wyre HW, et al. Water is safe and visually superior to saline in ureteroscopy: a prospective, randomized, double-blinded study. *J Urol.* 2016; 191: e280.
6. Pirani F, Makhani SS, Kim FY, et al. Prospective randomized trial comparing the safety and clarity of water versus saline irrigant in ureteroscopy. *Eur Urol Focus.* 2020; pii: S2405-4569(20)30066-3.
7. Talso M, Proietti S, Emiliani E, et al. Comparison of flexible ureterorenoscope quality of vision: an in vitro study. *J Endourol.* 2018; 32: 523-528.
8. Hawary A, Mukhtar K, Sinclair A, Pearce I. Transurethral resection of the prostate syndrome: almost gone but not forgotten. *J Endourol.* 2009; 23: 2013-2020.
9. Gravenstein D. Transurethral resection of the prostate (TURP) syndrome: a review of the pathophysiology and management. *Anesth Analg.* 1997; 84: 438-446.
10. Hahn RG. Transurethral resection syndrome after transurethral resection of bladder tumours. *Can J Anaesth.* 1995; 42: 69-72.
11. Gehring H, Nahm W, Zimmermann K, Fornara P, Ocklitz E, Schmucker P. Irrigating fluid absorption during percutaneous nephrolithotripsy. *Acta Anaesthesiol Scand.* 1999; 43: 316-321.
12. Chou CH, Chau T, Yang SS, Lin SH. Acute hyponatremia and renal failure following percutaneous nephrolithotomy. *Clin Nephrol.* 2003; 59: 237-238.
13. Siddiqui MA, Berns JS, Baime MJ. Glycine irrigant absorption syndrome following cystoscopy. *Clin Nephrol.* 1996; 45: 365-366.
14. Ichai C, Ciais JF, et al. Intravascular absorption of glycine irrigating solution during shoulder arthroscopy: A case report and follow-up study. *Anesthesiology.* 1996; 85: 1481-1485.
15. Istre O, Bjoennes J, Naess R, Hornbaek K. Postoperative cerebral oedema after transcervical endometrial resection and uterine irrigation with 1.5% glycine. *Lancet.* 1994; 344: 1187-1189.
16. Cybulski P, Honey RJ, Pace K. Fluid absorbtion during ureterorenoscopy. *J Endourol.* 2004; 18: 739-742.
17. Guzelburc V, Balasar M, Colakogullari M, et al. Comparison of absorbed irrigation fluid volumes during retrograde intrarenal surgery and percutaneous nephrolithotomy for the treatment of kidney stones larger than 2 cm. *Springerplus.* 2006; 5: 1707.
18. Zeltser I, Pearle MS, Bagley DH. Saline is our friend. *Urology.* 2009; 74: 28-29. ■