

Comparative evaluation of bilateral pudendal nerve blockade and periprostatic nerve block in transrectal ultrasound guided prostate biopsy: a prospective randomised trial

Rahmi Aslan¹, Akif Erbin², Recep Eryilmaz¹, Kerem Taken¹

¹Department of Urology, Yuzuncu Yil University Medical Faculty, Van, Turkey

²Department of Urology, Haseki Training and Research Hospital, Istanbul, Turkey

Citation: Aslan R, Erbin A, Eryilmaz R, Taken K. Comparative evaluation of bilateral pudendal nerve blockade and periprostatic nerve block in transrectal ultrasound guided prostate biopsy: a prospective randomised trial. Cent European J Urol. 2020; 73: 140-145.

Article history

Submitted: March 31, 2020

Accepted: May 29, 2020

Published online: June 19, 2020

Corresponding author

Akif Erbin

Haseki Training and Research Hospital
Department of Urology
Adnan Adivar street
34130 Istanbul, Turkey
phone: +90 506 543 1062
akiferbin@hotmail.com

Introduction Although the periprostatic nerve block (PNB) is accepted as the standard method for local anesthesia prior to transrectal ultrasound (TRUS)-guided prostate biopsy, it is not the most ideal method. We aimed to analyze the effectiveness and safety of bilateral pudendal nerve blockage (PuNB) by comparing with PNB.

Material and methods Between June 2019 and October 2019, a total of 108 patients with elevated serum prostate specific antigen values (PSA ≥ 4 ng/ml) and/or abnormal digital rectal examination findings were included in the study. After exclusion criteria, the remaining 91 patients were randomly divided into two groups as PuNB (n = 46) and PNB (n = 45). Pain during local anesthesia application was recorded as a visual analog scale (VAS) 1, pain during placement of the rectal probe and manipulation was recorded as VAS 2 and pain during needle penetration into prostate tissue and sampling was recorded as VAS 3.

Results No significant difference was found between the two groups with regard to age, body mass index, serum PSA, prostate volume and prostate cancer rates. Mean VAS-2 score was significantly lower in the PuNB group when compared with the PNB group. There was no significant difference in terms of VAS-1 and VAS-3 scores. There was no significant difference between the groups in terms of mild and severe complications.

Conclusions Both techniques are safe for TRUS-guided prostate biopsy; however, PuNB provided more effective pain control compared to PNB especially during placement of rectal probe and manipulation.

Key Words: periprostatic nerve block \leftrightarrow prostate biopsy \leftrightarrow pudendal nerve blockage

INTRODUCTION

In order to definitively diagnose prostate carcinoma, transrectal ultrasound (TRUS)-guided prostate biopsy is needed. This procedure often caused serious pain and discomfort in many patients, if one of the general anesthesia methods was not used. Severe pain can result the patient to move during the procedure, which can increase the rate of complications and decrease the number of cores that

can be taken. These factors can potentially decrease the accuracy of the final diagnosis [1]. Pain during TRUS-guided biopsy can be seen in three stages; 1. local anesthesia application; 2. placement of rectal probe and manipulation; and 3. needle penetration into prostate tissue and sampling. Ideal anesthesia should be effective for all three stages. Although the current European Association of Urology guideline still recommends periprostatic nerve block (PNB) for local anesthesia prior to TRUS-

guided prostate biopsy, it does not provide sufficient analgesia for all stages of biopsy [2]. In biopsies performed with PNB, pain is especially seen in the first and second stages. During PNB, lidocaine is injected into the bilateral junctions between the bladder, prostate, and seminal vesicle, with the intent to block the posterolateral neurovascular bundle that is responsible for supplying the main nerve to the prostate. The problem with PNB is that few nerve fibers that supply the superolateral and anterior part of the prostate and fibers supplying the anal sphincter and perianal region are not blocked by this procedure.

The pudendal nerve includes both sense and motor fibers. As the nerve passes through the Alcock's canal, it branches into the inferior rectal nerve (innervates the distal rectum and anal rhabdosphincter), the perineal nerve (innervates the striated urethral sphincter, the bulbospongiosus muscle, the ischio-cavernosus muscle, superficial transverse perineal muscle, and the labial skin), and the dorsal nerve of the clitoris [3]. Pudendal nerve blockage (PuNB) has been used to provide local anesthesia during some anorectal and gynecological procedures such as hemorrhoidectomy and transvaginal pelvic reconstructive surgeries [4, 5]. However, its role in urological procedures especially in prostate biopsy has not been thoroughly known. The purpose of the present study was to compare the effectiveness and safety of PuNB applied prior to TRUS-guided prostate biopsy with PNB which is accepted as the standard technique.

MATERIAL AND METHODS

Study design

The study was conducted in a tertiary university hospital. Between June 2019 and October 2019, a total of 108 patients with elevated serum prostate specific antigen values (PSA ≥ 4 ng/mL) and/or abnormal digital rectal examination (DRE) findings were included in the study. Among them, patients with anal fissure, fistula, hemorrhoid, inflammatory bowel disease, chronic prostatitis, previous history of prostate biopsy and anorectal surgery and patients with prostate less than 30 mL were excluded from the study (n = 17). The remaining 91 patients were randomly divided into two groups as PuNB group (n = 46) and PNB group (control group, n = 45). Block randomization was carried out by using the 'Statistical Analysis Software' system (StataCorp, College Station, TX, USA). The flow diagram of the study according to the Consolidated Standards of Reporting Trials (CONSORT) 2010 is presented in Figure 1 [6].

Demographic data, and procedural and postprocedural outcomes for both groups were prospectively recorded and analyzed. The design and aim of the study were explained to all participants and written informed consent was provided by the all participants. Before the procedure, all patients were instructed about how to assess pain and discomfort level using a visual analog scale (VAS) from 0 to 10, with an 11-point score (0 = no pain, 10 = intolerable pain). VAS scale was assessed by another urologist blinded to the biopsy procedure. Pain during local anesthesia application was recorded as VAS 1, pain during placement of rectal probe and manipulation was recorded as VAS 2 and pain during needle penetration into prostate tissue and sampling was recorded as VAS 3. While self-limiting rectal bleeding, hematuria and hematospermia were classified as mild complications, urosepsis, acute prostatitis, acute urinary retention, massive rectal bleeding, and allergic reactions were classified as severe complications.

Biopsy procedure

Ciprofloxacin (500 mg, per-oral) was started one day before for antibiotic prophylaxis and continued for 3 days after the procedure. Bowel cleansing was performed on the night before and on the morning of the day of the procedure. The transrectal prostate volume was calculated using the formula for a prolate ellipsoid (width x length x height x 0.52). All procedures were performed by a single experienced urologist.

Pudendal Nerve Blockage

In the lithotomy position, the perineum was cleaned with iodine solution. A DRE was carried out to localize the ischial spine. Bilateral PuNB was carried out transperineally using a 22-G, 20-cm spinal needle. The injection of 5 ml of 1% lidocaine (10 ml in total) was administered percutaneously, just posterior to the ischial spine at the attachment of the sacrospinous ligament, under DRE guidance (Figure 2). Five minutes later, the probe was reinserted and biopsy began after calculation of the transrectal prostate.

Periprostatic Nerve Block

In the lateral decubitus position, after the application of an intrarectal lubricant gel, 5 ml of 1% lidocaine (Jetocaine, Adeka, Turkey) was injected bilaterally with a 22-G, 20-cm spinal needle on each side (10 ml in total) into the neurovascular bundles

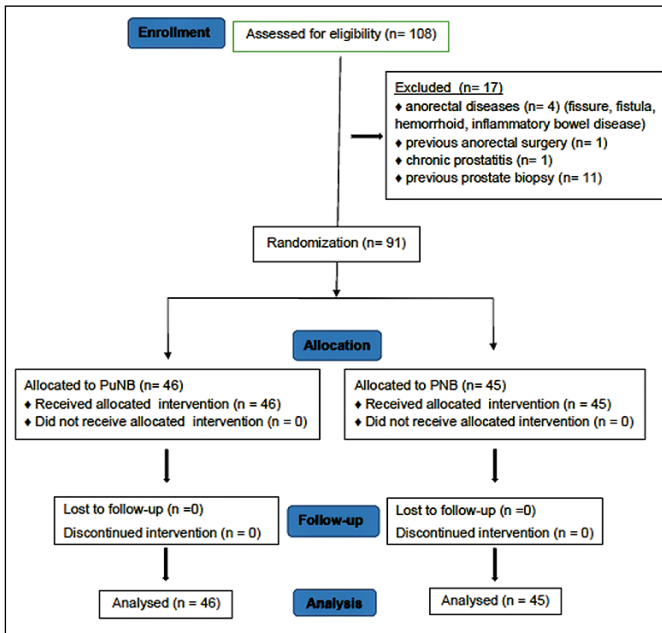


Figure 1. CONSORT flow-diagram for participants in the study.

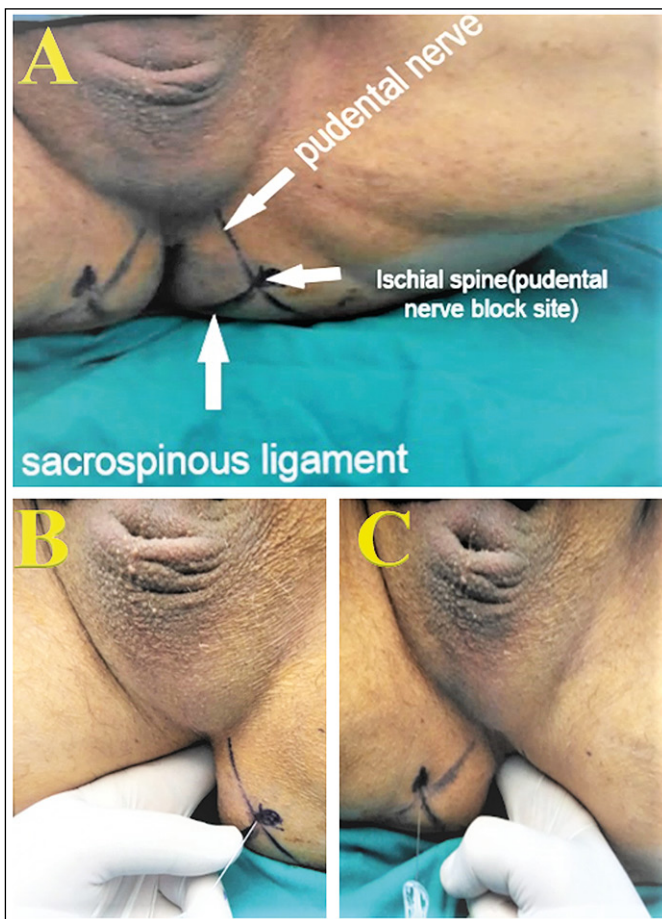


Figure 2. Perineal anatomical landmarks for PuNB application (A), Left-sided PuNB application (B) and right-sided PuNB application (C).

at the prostate-bladder-seminal vesicle angle, under TRUS guidance. Five minutes later, the probe was re-inserted and biopsy began after calculation of the transrectal prostate volume.

All biopsies were carried out using a Hitachi Hi Vision 5500 system (Hitachi Aloka Medical, Tokyo, Japan) and an 18-G, 20-mm side notch, automatic, disposable core biopsy needle (Mission; Bard Biopsy Systems, Tempe, AZ, USA). All procedures were performed by the same experienced urologist. All patients underwent a 12-core biopsy protocol, including six parasagittal and six lateral targeted cores covering the base, mid-zones and apex. The biopsy samples were numbered separately and examined by a uropathologist. All patients were kept under observation for 2 h after the procedure. Patients who did not have any complications were discharged. After 2 weeks, the patients were re-evaluated in terms of complications and histopathological results.

Statistical analysis

Data were analyzed using the Statistical Package for the Social Sciences software version 22 (SPSS, Chicago, IL, USA). Visual (histograms and probability plots) and analytical methods (Kolmogorov-Smirnov test) were used to determine whether the variables were distributed normally or not. Descriptive analyses are given using mean and standard deviation for normally distributed variables (VAS 1, VAS 2, VAS 3 scores) and categorical variables are given using frequency and percentages values. In order to compare the VAS scores between groups, one-way ANOVA was used. In order to assess the homogeneity of the variances, the Levene test was used. If a general significance was seen, dual post-hoc test was conducted using the Tukey test. For analysis between categorical variables, Chi-Square and Fisher's definitive tests were used. The statistical significance threshold was accepted as $p < 0.05$ for all analyses.

RESULTS

Table 1 Presents demographic characteristics of the patients. Mean age was 59.04 ± 7.6 and 60.9 ± 8.5 years in PuNB and PNB groups, respectively. No significant difference was found between the two groups with regard to age, body mass index, prostate volume, serum PSA and prostate cancer rates.

Table 2 presents VAS score assessments. Mean VAS-2 score was significantly lower in the PuNB group when compared with the PNB group. There

Table 1. Demographic characteristics of the patients

Variable	PuNB group (n:46)	PNB group (n:45)	p
Age (years), mean \pm sd	59.04 \pm 7.6	60.9 \pm 8.5	>0.05
BMI (kg/m ²), mean \pm sd	27.6 \pm 5.02	27.7 \pm 2.9	>0.05
PSA (ng/ml) mean	12.04 \pm 15.8	15.3 \pm 12.4	>0.05
Prostate volume, mean \pm sd	62.04 \pm 25.8	65.4 \pm 25.9	>0.05
Prostate cancer, n (%)	15 (32.6%)	15 (31.1%)	>0.05

PuNB – perineal pudendal nerve blockade; PNB – periprostatic nerve block;
BMI – body-mass index; PSA – prostate specific antigen

Table 2. Comparison of VAS scores between the groups

Variable	PuNB group (n:46)	PNB group (n:45)	p
VAS-1 (local anesthetic application), mean \pm sd	1.44 \pm 0.25	1.52 \pm 0.33	>0.05
VAS-2 (probe insertion and manipulation), mean \pm sd	2.08 \pm 0.89	3.88 \pm 1.29	<0.05
VAS-3 (sampling), mean \pm sd	2.73 \pm 0.99	2.55 \pm 1.09	>0.05

VAS – visual analogue scale; PuNB – pudendal nerve blockade;
PNB – periprostatic nerve block

Table 3. Comparison of complications between the groups

Variable	PuNB group (n:46)	PNB group (n:45)	p
Mild			
rectal bleeding, n (%)	0	1 (2.2%)	
hematuria, n (%)	1 (2.2%)	0	
Severe			
urinary retention, n (%)	0	1 (2.2%)	>0.05
acute prostatitis, n (%)	1 (2.2%)	0	
Total, n (%)	2 (4.3%)	2 (4.4%)	

PuNB – pudendal nerve blockade; PNB – periprostatic nerve block

was no significant difference in terms of VAS-1 and VAS-3 scores.

Table 3 presents analysis of complications. There was no complication during anesthesia administration in both groups. Total complication rates were 4.3% and 4.4% in PuNB and PNB groups, respectively. There was no significant difference in terms of mild and severe complications between the groups.

DISCUSSION

Although pain during TRUS-guided prostate biopsy may occur in all three stages mentioned, it is most often seen in the stage of placement of the rectal probe and manipulation [7]. Severe

pain at this first stage increases the anxiety of patients and this condition causes the sampling phase be more uncomfortable. All these situations may affect the success of the procedure. Periprostatic nerve block decreases pain only during needle penetration into prostate tissue and sampling but is not effective during placement of rectal probe and manipulation [8]. Although PNB technique introduced by Nash in 1996 is regarded as the standard method to overcome pain during TRUS-guided prostate biopsy, it does not provide adequate analgesic effect [9].

To date, several different analgesic techniques have been investigated to provide more effective analgesic control than PNB, which include intrarectal local anesthesia, perianal local anesthetic injection, various analgesics such as oral nonsteroidal anti-inflammatory agents and opioids, application of inhaled mixture of nitrous oxide and oxygen, selective low-dose spinal anesthesia, caudal block, and pelvic plexus block [10–16]. Although all these techniques provide more effective pain control alone when compared with placebo, none of them is better than PNB.

Although there is no perfect method for controlling pain during prostate biopsy, some more advantageous techniques than PNB have been described. In a recent study, Bolat et al. described a novel method named infiltration free local anesthesia technique (INFLATE) and compared with PNB. In the INFLATE group, a two-channel TEN-Stem eco basic device with two electrodes on both sides was used for pain control during the biopsy. They reported that although the mean preoperative and post-operative pain scores during probe insertion, biopsy and post-biopsy were similar between the groups, INFLATE using a TENS device could safely be used for pain control with the advantage of two fewer needle attempts with no increase in significant complications [17]. Senturk et al. compared the effectiveness of diclofenac suppository alone and PNB and reported that a 100 mg intrarectal diclofenac suppository showed similar analgesic effects as PNB with 10 cc of 1% lidocaine and that introduction of a 100 mg intrarectal diclofenac suppository was well tolerated by patients and no side effects of the drug were encountered [18].

In a small retrospective study, Inal et al. compared the five groups (no anesthesia, PNB, unilateral PuNB, intrarectal lidocaine gel and, combination of PNB + intrarectal lidocaine gel) and reported that using either a combination of intrarectal lidocaine gel and PNB or solely unilateral PuNB for prostate biopsy procedures provides efficient pa-

tient comfort by reducing pain both during probe insertion and needle passing through the prostate gland [19]. Adsan et al. reported their results in a small randomized placebo-controlled study and stated that unilateral PuNB (26 patients) was superior to placebo (25 patients) in reducing pain during both biopsy and probe manipulation phases [20]. We compared bilateral PuNB with PNB technique and showed that it was more effective than PNB. Because of the absence of anal sphincter relaxation in biopsy with PNB, severe pain can be seen especially in young patients during probe placement for local anesthesia. This may adversely affect both the phase of local anesthesia administration and sampling with the PNB technique. Local anesthesia application during PuNB is simpler than PNB because of the fact that there is no need to place a probe into the rectum. Additionally, the motor fibers of the pudendal nerve reduce the tone of the external sphincter [21]. These advantages enable PuNB to be a superior method than PNB. Furthermore, PuNB is a reasonable technique for complications.

Although the present study was a randomized prospective study, it has some limitations, mainly related to the lack of double-blind nature. Another important limitation is that there were no specific assessments in terms of patient stratifications, which are based on age, BMI, comorbidities or prostate volume. These variables can affect the pain perception among people. Despite these limi-

tations, to our knowledge, the present study is the first report on the randomized comparison of bilateral PuNB with PNB during TRUS-guided prostate biopsy. We believe that the present study will contribute to the literature by guiding the future development of more effective analgesic methods than PNB.

CONCLUSIONS

Although PNB is accepted as the standard method for TRUS – guided prostate biopsy, it is not the ideal type of anesthesia for all steps of the procedure. Our results suggest that both PuNB and PNB techniques are safe for patients undergoing TRUS-guided prostate biopsy; however, PuNB provided more effective pain control compared to PNB especially during the phase of placement of rectal probe and manipulation.

STATEMENT OF ETHICS

The present prospective randomized controlled study was approved by the internal institutional review board (date: 29/05/2019, approval number; 14).

FUNDING SOURCES

This research received no specific grant from any funding agency in the public, commercial or not-for-profit sectors.

CONFLICTS OF INTEREST

The authors declare no conflicts of interest.

References

- Kim DK, Lee JY, Jung JH, et. al. What is the most effective local anesthesia for transrectal ultrasonography-guided biopsy of the prostate? A systematic review and network meta-analysis of 47 randomized clinical trials. *Sci Rep.* 2019; 9: 4901.
- Mottet N, van den Bergh R.C.N, et al. EAU Guidelines on Prostate Cancer 2019. <https://uroweb.org/guideline/prostate-cancer/#5>.
- Schraffordt SE, Tjandra JJ, Eizenberg N, Dwyer PL. Anatomy of the pudendal nerve and its terminal branches: a cadaver study. *ANZ J. Surg.* 2004; 74: 23-26.
- Anannamcharoen S, Cheeranont P, Boonya-usadon C. Local perianal nerve block versus spinal block for closed hemorrhoidectomy: a randomized controlled trial. *J Med Assoc Thai.* 2008; 91: 1862-1866.
- Abramov Y, Sand PK, Gandhi S, Botros SM, Miller JJ, Koh EK. The effect of preemptive pudendal nerve blockade on pain after transvaginal pelvic reconstructive surgery. *Obstet Gynecol.* 2005; 106: 782-788.
- Schulz KF, Altman DG, Moher D. CONSORT Group. CONSORT 2010 Statement: Updated guidelines for reporting parallel group randomised trials. *J Clin Epidemiol.* 2010; 63: 834-840.
- Luscombe CJ, Cooke PW. Pain during prostate biopsy. *Lancet.* 2004; 363: 1840-841.
- Kravchick S, Peled R, Ben-Dor D, Dorfman D, KesariD, Cytron S. Comparison of different local anesthesia techniques during TRUS-guided biopsies: a prospective pilot study. *Urology.* 2005; 65: 109-113.
- Nash PA, Bruce JE, Indudhara R, Shinohara K. Transrectal ultrasound guided prostatic nerve blockade eases systematic needle biopsy of the prostate. *J Urol.* 1996; 155: 607-609.
- Chang SS, Alberts G, Wells N, Smith JA Jr, Cookson MS. Intrarectal lidocaine during transrectal prostate biopsy: results of a prospective double-blind randomized trial. *J Urol* 2001; 166: 2178-2180.
- Kravchick S, Yoffe B, Cytron S. Modified perianal/pericapsular anesthesia for transrectal biopsy of prostate in patients with anal rectal problems. *Urology.* 2007; 69: 139-141.
- Pendleton J, Costa J, Wludyka P, Carvin DM, Rosser CJ. Combination of oral tramadol, acetaminophen and 1% lidocaine induced periprostatic nerve block for pain control during transrectal ultrasound

- guided biopsy of the prostate: a prospective, randomized, controlled trial. *J Urol*. 2006; 176: 1372-1375.
13. Manikandan R, Srirangam SJ, Brown SC, O'Reilly PH, Collins GN. Nitrous oxide vs. periprostatic nerve block with 1% lidocaine during transrectal ultrasound guided biopsy of the prostate: a prospective, randomised, controlled trial. *J Urol*. 2003; 170:1881-1883.
 14. Kucur M, Goktas S, Kaynar M, et al. Selective Low-Dose Spinal Anesthesia for Transrectal Prostate Biopsy: A Prospective and Randomized Study. *J Endourol*. 2015; 29: 1412-1417.
 15. Horinaga M, Nakashima J, Nakanoma T. Efficacy compared between caudal block and periprostatic local anesthesia for transrectal ultrasound-guided prostate needle biopsy. *Urology*. 2006; 68: 348-351.
 16. Kim DK, Hah YS, Kim JW, et al. Is Pelvic Plexus Block Superior to Periprostatic Nerve Block for Pain Control during Transrectal Ultrasonography-Guided Prostate Biopsy? A Double-Blind, Randomized Controlled Trial. *J Clin Med*. 2019; 8: 557.
 17. Bolat MS, Cinar O, Asci R, Buyukalpelli R. A novel method for pain control: infiltration free local anesthesia technique (INFLATE) for transrectal prostatic biopsy using transcutaneous electrical nerve stimulation (TENS). *Int Urol Nephrol*. 2019; 51: 2119-2126.
 18. Senturk AB, Yayıtköyl M, Ekici M, Sari S, Demir E, Çakirođlu B. Comparing use of lidocaine periprostatic nerve block and diclofenac suppository alone for patients undergoing transrectal ultrasound guided prostate biopsy. *Cent European J Urol*. 2018; 71: 38-42.
 19. Inal G, Adsan O, Ugurlu O, Kaygisiz O, Kosan M, Cetinkaya M. Comparison of four different anesthesia methods for relief of all pain during transrectal ultrasound-guided prostate biopsy. *Int Urol Nephrol*. 2008; 40: 335-339.
 20. Adsan O, Inal G, Ozdođan L, Kaygisiz O, Uđurlu O, Cetinkaya M. Unilateral pudendal nerve blockade for relief of all pain during transrectal ultrasound-guided biopsy of the prostate: a randomized, double-blind, placebo-controlled study. *Urology*. 2004; 64: 528-531.
 21. Zermann DH, Ishigooka M, Doggweiler R, Schmidt RA. Neurourological insights into the etiology of genitourinary pain in men. *J Urol*. 1999; 161: 903-908. ■