

Buccal mucosal graft versus penile skin flap urethroplasty for long segment penile urethral stricture: a prospective randomized study

Ahmed Issam Ali¹, Amr Abdel Hamid², Mohammed Abdou Abdel-Rassoul³, Ehab M Galal¹, Mohammed G.S. Hasanein¹, Mohamed Abd Elmalek Hassan¹, Mamdouh M. El-Hawy¹

¹Minia University Hospital, School of Medicine, Department of Urology, Minia, Egypt

²Minia University, School of Medicine, Department of Urology, Minia, Egypt

³Cairo University, School of Medicine, Al Kasr Alaaini, Cairo, Egypt

Citation: Ali AI, Hamid AA, Abdel-Rassoul MA, et al. Buccal mucosal graft versus penile skin flap urethroplasty for long segment penile urethral stricture: a prospective randomized study. Cent European J Urol. 2019; 72: 191-197.

Article history

Submitted: Feb. 27, 2019

Accepted: May 31, 2019

Published online: June 29, 2019

Corresponding author

Ahmed Issam Ali
Minia University Hospital
School of Medicine
Urology Department
61111 Minia, Egypt
ahmed_issam79@yahoo.com

Introduction The aim of this study was to analyze the outcomes of dorsolateral onlay buccal mucosal graft (BMG) and ventral onlay local penile skin flap (LPF) urethroplasty in the management of long segment penile urethral stricture (PUS).

Material and methods Through a prospective study conducted between October 2014 and May 2018, 84 patients with long segment PUS were randomly assigned to receive either dorsolateral onlay BMG (Group 1 which included 42 patients) or ventral onlay PSF urethroplasty (Group 2 which included 42 patients). The success rate and surgical outcomes were compared in both groups.

Results The success rate was 92.9% in Group 1 and 85.7% in Group 2 ($p = 0.5$). Postoperative short segment urethral stricture at the site of proximal anastomosis was reported in 3 patients in Group 1. Six patients in Group 2 were considered as a treatment failure, 3 of them due to recurrence of long segment urethral stricture after 6 months, and 3 patients developed ring urethral stricture at the site of proximal anastomosis managed by direct vision internal urethrotomy.

Conclusions On an intermediate term follow-up, dorsolateral onlay BMG and ventral onlay LPF provide similar success rates in penile urethroplasty, with essentially comparable postoperative morbidity. However, further studies with bigger sample sizes and longer follow-up periods may be required to determine subtle differences between both techniques.

Key Words: buccal ◊ flap ◊ graft ◊ mucosa ◊ penile ◊ stricture ◊ urethra

INTRODUCTION

Penile urethral reconstruction proves to be a continuous challenge as no perfect technique is considered for all patients with this problem. Among all the methods used for treatment of urethral stricture, the substitution urethroplasty with tissue transfer using either flap or graft is the gold standard treatment option for long segment urethral strictures [1].

In 1993, McAninch described a circular fasciocutaneous flap for the management of penile urethral

stricture up to 15 cm that showed excellent cosmetic and functional outcomes due to this being a hairless, flexible flap with a rich vascular supply [1–4].

Buccal mucosal graft (BMG) was rediscovered and popularized in 1992 by Burger et al., then El-Kassaby et al. in 1993 published a series using buccal mucosal graft to repair anterior urethral stricture. Buccal mucosal graft became an ideal urethral substitute due to easy harvesting, hairlessness and compatibility in a wet environment [5, 6].

To the best of our knowledge, few prospective studies in the literature compared penile skin flap versus buccal mucosa graft urethroplasty. In the present study, we analyzed the outcomes of dorsolateral onlay buccal mucosal graft (BMG) and ventral onlay local penile skin flap (LPF) urethroplasty in the management of long segment penile urethral strictures.

MATERIAL AND METHODS

Through a prospective randomized study, patients with long segment penile urethral stricture who presented to the Urology Department at Kasr-Alaini Hospital, Cairo and the Urology Department at Minia University hospital, Minia in the period between October 2014 and May 2018, were included in our study.

Long segment penile urethral stricture was defined as a stricture with a length of more than 1 cm with spongiofibrosis and/or previous failed urethral dilatation, direct vision internal urethrotomy (DVIU) or urethroplasty.

A total of 84 patients with long segment penile urethral stricture were randomly assigned to receive either dorsolateral onlay buccal mucosal graft urethroplasty (42 patients) or ventral onlay local penile skin flap urethroplasty (42 patients).

Patients with lichen sclerosus and those with history of hypospadias repair were excluded from our study. All patients were subjected to clinical history, physical examination, full preoperative laboratory investigations, urine analysis and urine culture, pelvi-abdominal ultrasonography for assessment of post void residual urine and upper tract involvement, uroflowmetry, retrograde urethrography, voiding cysto-urethrography and urethroscopy in selected cases.

Patients were randomized to either of the two groups using the opaque envelope method. The surgical procedures were performed in two centers, KasrAlaini Hospital, Cairo and the Urology Department at Minia University hospital. Two teams of well-trained surgeons with equivalent experience performed the procedures in our study.

Surgical technique

For local penile flap urethroplasty, the urethra does not have to be mobilized off the corporal bodies. A 22 or 24 Fr bougie is inserted to detect the distal end of the stricture, then a ventral urethrotomy incision is performed onto the bougie.

The urethrotomy is continued with tenotomy scissor proximally throughout the strictured segment including 1 to 2 cm both proximally and dis-

tally through the healthy urethral lumen, so that a 26–30 Fr bougie is accepted in both directions, then the length of the defect is measured.

Three types of urethral flaps were used depending on the location and length of the stricture. The longitudinal (Orandi) flaps, McAninch (circular) flaps or the (Q) flaps. A Foley catheter is left in place and a gentle pressure dressing is applied.

For Buccal mucosal graft urethroplasty surgical technique, the urethra does not have to be mobilized off both corporal bodies in dorsolateral onlay technique, but we do dissect the corpus spongiosum free on one side to the dorsal midline attachments. The urethrotomy incision is done dorsolaterally, and then urethrotomy is continued with tenotomy scissors proximally and distally through the stricture and for at least 1 cm into healthy urethra in both directions, a 26–30 Fr bougie is inserted in both directions, then the length of the defect is measured. After that, the oral mucosa is harvested. The width of the graft is around 15–20 mm. Graft defatting is done carefully to remove the underlying tissue. If needed, another graft may be harvested from the other cheek using the same technique.

The graft is fixed to the corpora cavernosa and several quilting sutures are added to it. Small incisions along the graft are made to prevent hematoma or edema formation. After introduction of a 16 Fr silicone catheter, the edges of the stricturotomy are then sutured to the graft, as well as to the corpora cavernosa using 4-0 vicryl sutures, and a gentle pressure dressing is applied. Operative time was documented in all patients.

The patients were ambulatory on the first postoperative day and discharged on the first or second postoperative day. After four weeks of surgery, pericatheter urethrography was done and the catheter was removed if no extravasation detected. Patients with wound infection at the level of suture line had extended catheterization for 1 or 2 more weeks.

Uroflowmetry, retrograde urethrography and micraturating cysto-urethrography were done after 3 and 6 months, or earlier if obstructive symptoms arose. The follow-up thereafter included symptomatic assessment and uroflowmetry every 6 months. Urethrography was performed only if symptoms or uroflowmetry suggested recurrent stricture.

The criteria for successful reconstruction were peak flow rate >15 ml/sec [7] and no postoperative requirement of any kind of instrumentation.

Statistical methods

Data management and analysis were performed using SPSS program; version 21. The graphs were

done by Microsoft Excel 2010. The numerical data were statistically presented in terms of range, mean, standard deviation and median. Categorical data were summarized as percentages. Comparisons between numerical variables of two groups were done by Mann-Whitney Rank Sum test for non-parametric data. Comparing categorical variables were done by Chi-square test. All P-values were two tailed and considered significant when p-values were less than 0.05.

At 80% study power and an assumed significance level of 0.05, a minimum number of 41 patients were required to be in each group to detect an effect size of 0.3 (minimally detectable difference of categorical clinical response which is success versus failure in this study).

RESULTS

A total number of 84 patients who presented with long segment penile urethral stricture were enrolled in our study (Figure 1). Forty-two patients underwent buccal mucosal grafting (BMG) and 42 patients underwent local penile flap (LPF) urethral reconstruction, with mean age of 37.1 ± 17.4 years for buccal mucosal graft group and 47.4 ± 17.9 years for local penile skin flap group.

The mean follow-up period was 16.5 ± 7.3 months for the BMG group, and 13.1 ± 5.4 months for the LPF group. The median urethral stricture length assessed preoperatively using combined ascending and voiding urethrography was 57.5 mm in the BMG group (range: 30–140 mm) and 70 mm in the LPF group (range 20–110 mm). A discrepancy in stricture length was noticed when the stricture length was assessed intraoperatively. The intraoperative median urethral stricture length was 67.5 mm in the BMG group (range 40–140 mm) and 85 mm in the LPF group (range 20–120 mm) (Tables 1 and 2).

All patients in the BMG group underwent dorsolateral onlay graft urethroplasty. In the LPF group, three types of local penile flaps were used depending on the location and length of the stricture: Orandi flap in 9 patients (21.4%), McAninch flap in 24 patients (57.1%) and Q flap in 9 patients (21.4%) (Table 2).

Patients were followed up with pericatheter urethrogram before catheter removal, no extravasation of contrast was detected in any patient. Patients were followed up thereafter with uroflowmetry and RUG with VCUG after 3 months.

Mean peak flow rate was 23 ± 7.5 ml/s in the BMG group and 19.6 ± 5.9 ml/s in the LPF group ($p = 0.2$).

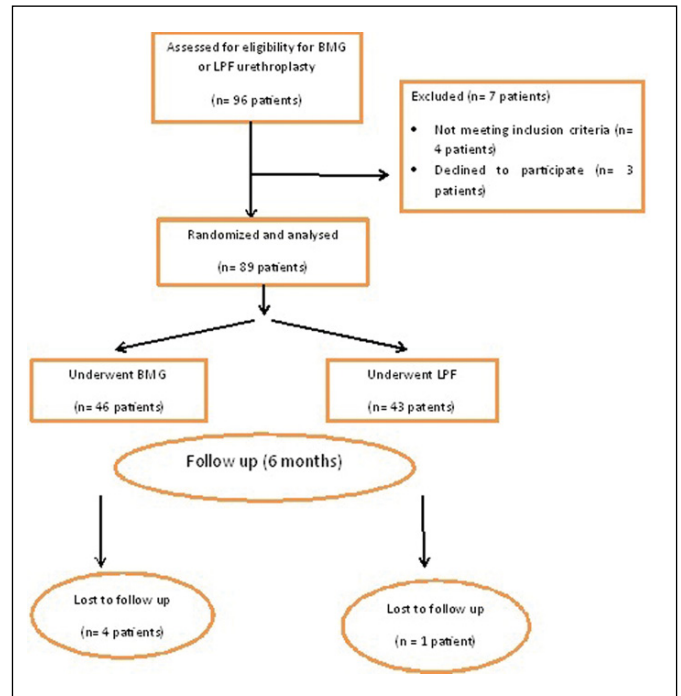


Figure 1. Consort diagram.

Table 1. Preoperative data

Etiology			
Inflammatory	21 (50%)	9 (21.4%)	
Post-catheterization	18 (42.9%)	6 (14.3%)	0.2
Idiopathic	3 (7.1%)	24 (57.1%)	
Iatrogenic trauma	0 (0%)	3 (7.1%)	
VIU pre-repair			
Yes	15 (35.7%)	27 (64.3%)	0.1
No	27 (64.3%)	15 (35.7%)	
UTI	24 (57.1%)	36 (85.7%)	0.09
Length of urethral stricture in mm			
Range	30–140	20–110	0.9
Median	57.5	70	

In both groups, three patients had peak flow rate (Q_{max}) less than 15 ml/s at 3 months of follow-up. In the LPF group, a further three patients developed stricture with peak flow rate less than 15 ml/s at 1 year of follow-up.

With regards to postoperative complications, six patients (14.3%) in each group had wound infection (Clavien-Dindo classification grade I), that was treated by frequent dressing and antibiotics according to wound swab culture and sensitivity results (Table 3).

In the LPF group, three patients (7.1%) developed small distal penile fistula. A further three patients (7.1%) in the LPF group developed postoperative

Table 2. Intraoperative data

	Buccal Mucosa Graft Group (No. = 42)	Local Penile Flap Group (No. = 42)	p-value
Length of urethral stricture intraoperatively (mm)			
Range	40–140	20–120	0.8
Median	67.5	85	
Operative time (min)			
Mean ±SD	197.14 ±23.7	192.14 ±34.4	0.7
Type of repair in local penile flap Group	No.	%	
Orandi technique	9	21.4	
McCanich technique	24	57.1	
Q technique	9	21.4	
Total	42	100	

Table 3. Postoperative data

	Buccal Mucosa Graft Group (No. = 42) (%)	Local Penile Flap Group (No. = 42) (%)	p-value
Follow-up period in months			
Mean ±SD	12.5 ±7.3	9.1 ±5.4	0.2
Uroflow Qmax (ml/sec)			
Mean ±SD	23 ±7.5	19.6 ±5.9	0.2
Less than 15	3 (7.1%)	6 (14.3%)	
More than 15	39 (92.9%)	36 (85.7%)	0.5
Early complication	No. (%)	No. (%)	
No	36 (85.7%)	33 (78.6%)	0.6
Wound infection	6 (14.3%)	6 (14.3%)	
Penile curvature (chordee)	No. (%)	No. (%)	
No chordee	42 (100%)	39 (92.9%)	0.3
Mild chordee	0 (0%)	3 (7.1%)	
Recession of meatus	0 (0%)	3 (7.1%)	0.3
Limitation in mouth opening	3 (7.1%)	0 (0%)	0.3
Early fistula	0 (0%)	3 (7.1%)	0.3
Success or failure in each group	Buccal Mucosa Graft Group (No. = 42) (%)	Local Penile Flap Group (No. = 14) (%)	
Success	No. (%)	No. (%)	0.5
	39 (92.9%)	36 (85.7%)	

mild degree of penile chordee documented by side view photography of an erect penis.

In the LPF group, three patients (7.1%) had recession of the meatus to the subcoronal position. These patients were offered surgical correction; however, they were satisfied with their surgical outcomes and refused further corrections.

Three patients (7.1%) in the LPF group presented with ring urethral stricture treated by direct vision internal urethrotomy.

In regards to oral complications in the BMG group, all patients had mild degree of pain at the donor site, that was self-limited and disappeared one week after surgery.

Three patients had mild limitation in mouth opening that improved with time. Mouth numbness and salivary disturbance did not occur in any case.

In our study, development of postoperative urethral stricture was considered a failure of the procedure. The success rate in the BMG group was 92.9%, three patients had small urethral stricture with peak flow rate less than 15 ml/s (Table 3).

The success rate in the LPF group was 85.7%. Three patients developed long segment urethral stricture with peak flow rate >15 ml/s at six months after surgery, and another three patients developed small urethral stricture treated by direct vision internal urethrotomy.

The success rates did not show statistical significance between both groups ($p = 0.5$).

DISCUSSION

Barbagli et al. stated that: "In our opinion, reporting on a small group of homogeneous urethral conditions may provide more information and make a stronger 'surgical' statement" [8].

All reconstructive urologists are aware that there is a difference in surgical steps, possible complications and results between penile urethroplasty and bulbar urethroplasty using one stage flap or graft techniques. It is also well known that the etiology and length of the stricture affect the results of urethroplasty procedures.

For these reasons, we designed our study to be a randomized prospective study evaluating the results of repair of only long segment penile urethra strictures using either buccal mucosa graft or penile skin flap, excluding complex cases of lichen sclerosus and those with history of previous hypospadias repair as these cases might affect our randomization.

In our study, we assessed the stricture length preoperatively using combined RUG and VCUG. The mean urethral stricture length in the BMG group was 57.5 mm (range 30–140 mm) and in the LPF group it was 70 mm (range 20–110 mm). When the stricture length was detected intraoperatively, we found a discrepancy in stricture length varying between 10 to 20%. The reason for this discrepancy is that we had to open the urethra at the site of stricture until we reached healthy urethral tissue on both ends.

Given the previous observation, we believe that intraoperative assessment is the most reliable method for assessing the length of urethral stricture.

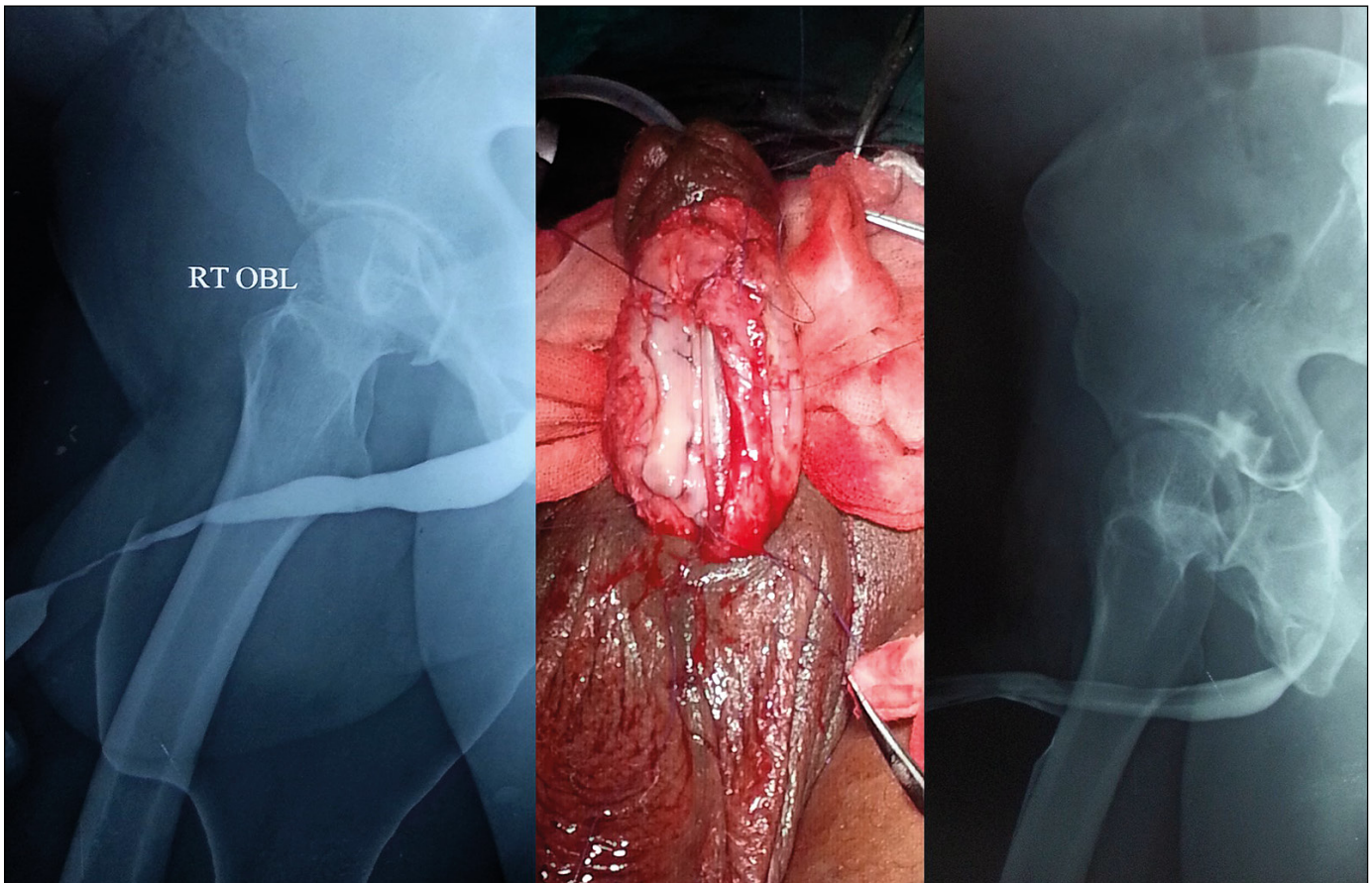


Figure 2. 62 year old male patient with post-catheterization penile urethral stricture 6 cm in length. Patient had previous history of DVIU. Dorsolateral onlay buccal mucosa graft urethroplasty was performed. (From left to right: preoperative ascending urethrogram, intraoperative buccal mucosal graft placement and post operative ascending urethrogram). .

Nitin Gupta and colleagues compared the retrograde urethrography (RUG) and the sono-urethrography (SUG) and also concluded that RUG underestimated the length of the stricture compared to that measured by SUG. Gupta et al. also reported that the length of urethral stricture measured by SUG is close to the intraoperative estimated urethral length [10]. Our study is lacking the SUG assessment of preoperative urethral stricture length which may be considered as a shortcoming of the study.

Therefore, we claim that RUG is a useful procedure to assess the stricture site and length, but data should be interpreted carefully and the reconstructive urologist must be experienced and have enough tools to deal with any intraoperative surprises.

In a series of 43 patients undergoing dorsal onlay BMG urethroplasty for penile strictures, Dubey et al. reported that 28 of these cases underwent single-stage urethroplasty and 15 cases underwent staged urethroplasty. Two-stage procedures were done only when the preoperative caliber was < 6 Fr

or the urethral plate was nonviable. They reported success rates of 85.7% for single stage urethroplasty and 86.7% for staged urethroplasty, and the majority of recurrences were managed successfully with DVIU [9].

In the present study, the success rate in the BMG group was 92.9%, three patients in this group developed a small urethral stricture, one of them with preoperative urethral stricture length of 10 cm developed a small urethral stricture at the site of proximal anastomosis in the 8th month after surgery.

Guido Barbagli and colleagues in their retrospective study analyzed the outcome of one-stage penile urethroplasty using a flap or graft in a homogeneous series of patients, and reported a lower success rate in the local penile flap group (67% success rate for one stage LPF, 82% for oral mucosal graft group [12]. On the other hand, in a study comparing dorsal onlay BMG versus LPF urethroplasty for anterior urethral strictures, Dubey and colleagues reported a success rate of 89.9% and 85.6% for BMG and LPF respectively [9].

In the present study, three different types of local penile flaps were used depending on location and length of the stricture. The heterogenous usage of penile flaps in urethral reconstruction may have led to higher success rates and better outcomes in our results compared to Guido Barbagli and colleagues who used only one type of flaps [12].

Raj Kumar Mathur and colleagues reported that the median peak flow rate after local skin flap urethroplasty was 26 ml/s (range 6–35) [13]. In another study, Hussein Aldaqadossi and colleagues mentioned that the average peak flow rate after dorsal inlay buccal mucosal graft urethroplasty was 23.4 ml/s [14].

In our study, the mean peak flow rate was 23 ± 7.5 ml/s in the BMG group, which was higher than that of the LPF group (19.6 ± 5.9 ml/s), however this difference was statistically insignificant ($p = 0.2$).

in regards to the incidence of dye extravasation during voiding cystourethrogram, Dubey and colleagues, compared dorsal onlay BMG versus LPF urethroplasty for anterior urethral strictures and they reported one case out of 27 in the BMG urethroplasty group and 2 cases out of 28 in the LPF urethroplasty group had mild extravasation of dye during voiding cystourethrogram that was performed at 3 weeks post-operative [9].

Simonato et al. reported in their study that two cases out of 29 cases post lingual mucosal graft urethroplasty had extravasation after two weeks of surgery; both cases were managed by prolonged catheterization [15].

In our study, peri-catheter urethrography was performed in all patients after 4 weeks of surgery. Two patients in the BMG group and one patient in the LPF group developed wound infection with increased risk of wound dehiscence. In these patients the catheters were left in place for an extra week.

In our opinion, the main reason of normal peri-catheter urethrography with no incidence of extravasation detected in any of our cases is related to the longer duration of catheterization.

Regarding postoperative complications, Dubey et al. in their prospective study on 55 patients with anterior urethral strictures who had either BMG (27 patients) or LPF (28 patients) urethroplasty, reported that 2 patients in each group had postoperative hematoma and one patient in the LPF group had wound infection. In the LPF group, 6 patients developed superficial penile skin necrosis that healed within 6 weeks postoperatively. One patient developed extensive skin loss managed by split skin grafting. Two patients in the LPF group and one patient in the BMG group had mild extravasation

of dye on VCUg at 3 weeks after surgery. Two patients in the LPF group developed slight penile torsion that did not interfere with sexual intercourse. In the BMG group, six patients (25.7%) complained of minor oral morbidity that was resolved after 4 weeks postoperatively. Four patients developed perioral numbness at the early postoperative period. One patient developed a mucus retention cyst which resolved spontaneously [9].

In our study, six patients (14.3%) in each group developed wound infection that was managed by frequent dressing and antibiotics according to wound swab culture and sensitivity. In the LPF group, three patients (7.1%) developed small distal penile fistula, and another three patients (7.1%) developed mild chordee (penile curvature) postoperatively. For all patients with postoperative penile curvature, no surgical intervention was performed. No patient in the buccal mucosal graft group developed penile curvature.

In the LPF group, three patients (7.1%) had recession of the meatus ending in subcoronal position of the meatus; they were offered correction, but they refused ensuring that they are satisfied with this outcome.

In the BMG group, all of our patients had mild pain at the donor site that was self-limited. Three patients had mild limitation of mouth opening that improved with time.

Study limitations

Our study had an intermediate length of postoperative follow-up period and we recommend further prospective studies with longer periods of follow-up to confirm our study conclusions and recommendations.

CONCLUSIONS

On an intermediate term of follow-up, dorsolateral onlay buccal mucosal graft and ventral onlay penile skin flap have similar success rates in penile urethroplasty, with essentially comparable postoperative morbidity.

In our study we also concluded that intraoperative assessment of urethral stricture length is more accurate than preoperative assessment performed by retrograde urethrogram and we recommend that reconstructive urologists should have enough experience and different tools to deal with any intraoperative surprises.

CONFLICTS OF INTEREST

The authors declare no conflicts of interest.

References

1. Gonzalez C. Penile urethral stricture reconstruction- flap or graft? *Flap. J Urol.* 2011; 186: 376-377.
2. Carson CC. Editorial. Urethroplasty: a model for international progress in urology. *Contemp Urol.* 2006; 18: 11.
3. Orandi A. One-stage urethroplasty. *Br J Urol.* 1968; 40: 717-719.
4. McAninch JW. Reconstruction of extensive urethral strictures: circular fasciocutaneous penile flap. *J Urol.* 1993; 149:488-491.
5. Humby G. A one-stage operation for hypospadias repair. *Br J Surg.* 1941; 29: 84-92.
6. El-Kasaby AW, Fath-Alla M, Noweir AM, et al. The use of buccal mucosa patch graft in the management of anterior urethral strictures. *J Urol.* 1993; 149: 276-278.
7. Heyns Chris F. Follow-Up strategies after urethral stricture treatment. *Advanced male urethral and genital reconstructive surgery.* Springer New York; 2014: 413-25.
8. Barbagli Guido and Massimo Lazzeri. Can reconstructive urethral surgery proceed without randomised controlled trials? *Eur Urol.* 2008: 709-711.
9. Dubey D, Vijjan V, Kapoor R, et al. Dorsal onlay buccal mucosa versus penile skin flap urethroplasty for anterior urethral strictures: results from a randomized prospective trial. *J Urol.* 2007; 178: 2466-2469.
10. Gupta N, Dubey D, Mandhani, A et al. Urethral stricture assessment: a prospective study evaluating urethral ultrasonography and conventional radiological studies. *BJU Int.* 2006; 98: 149-153.
11. Dubey D, Kumar A, Mandhani A, et al. Buccal mucosal urethroplasty: a versatile technique for all urethral segments. *BJU Int.* 2005; 95: 625-629.
12. Guido Barbagli, Guiseppe Morgia and Massimo Lazzeri. Retrospective outcome analysis of one-stage penile urethroplasty using a flap or graft in a homogeneous series of patients. *BJU Int.* 2008; 102: 853-860.
13. Mathur RK, Nagar M, Mathur R, et al. Single-stage preputial skin flap urethroplasty for long-segment urethral strictures: evaluation and determinants of success. *BJU Int.* 2014; 113: 120-126.
14. Aldaqadossi H, El Gamal S, El-Nadey M, et al. Dorsal onlay (Barbagli technique) versus dorsal inlay (Asopa technique) buccal mucosal graft urethroplasty for anterior urethral stricture: a prospective randomized study. *Int J Urol.* 2014; 21: 185-188.
15. Simonato A, Gregori A, Ambruosi C, et al. Lingual mucosal graft urethroplasty for anterior urethral reconstruction. *Eur Urol.* 2008; 54: 79-87. ■