

Acute pancreatitis as rare complication of the right radical transperitoneal open nephrectomy

Badereddin Mohamad Al-Ali¹, Felix Thimary², Karl Pummer¹

¹Department of Urology, Medical University Graz, Austria

²Department of Radiology, Medical University Graz, Austria

KEY WORDS

acute pancreatitis ► transperitoneal nephrectomy

ABSTRACT

Radical open nephrectomy is considered the standard treatment for kidney tumors or masses greater than 10 cm. We present a rare case of acute pancreatitis that occurred after right radical transperitoneal nephrectomy, which was treated by nonsurgical conservative interventions.

The incidence of acute pancreatitis after renal surgery is not known in the literature.

A 56-year-old man developed acute pancreatitis post-operatively after radical transperitoneal nephrectomy. An initial CT scan showed an enlarged pancreas with hypodense, heterogeneous consistency and with peripancreatic, perihepatic, mesenteric, and pelvic fluid collections. This complication was managed conservatively.

INTRODUCTION

According to the EAU Guidelines [4] nephron-sparing surgery (NSS) has a similar oncological outcome to that of radical surgery. However, NSS is not suitable in some patients with localized renal cell carcinoma (RCC) because: 1) of locally advanced tumor growth, 2) partial resection is not technically feasible because the tumor is in an unfavorable location, 3) and/or significant deterioration of

the patient's general health. In these situations the gold standard curative therapy remains radical nephrectomy, which includes radical removal of the tumor-bearing kidney. Acute pancreatitis has not yet been described in the published literature as a complication of radical nephrectomy.

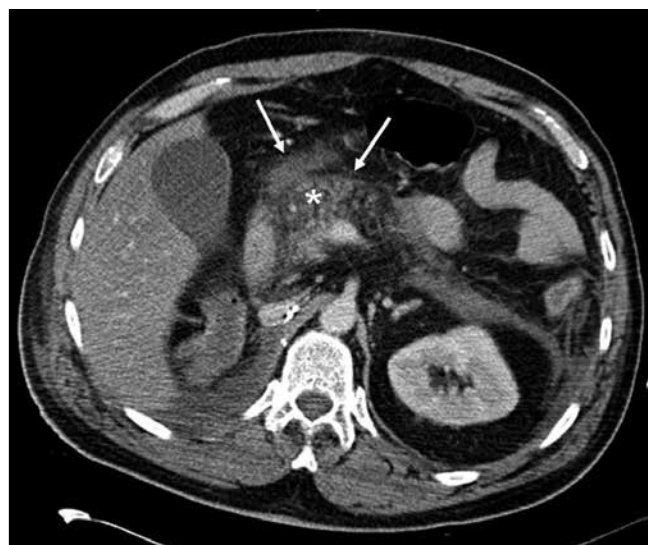
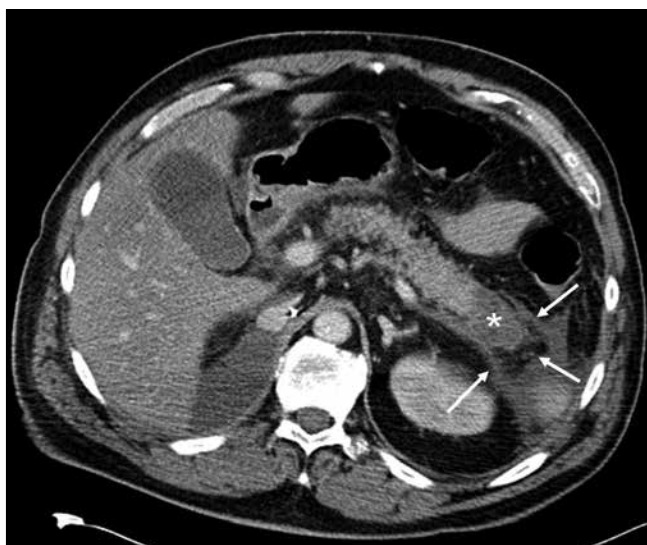
CASE REPORT

We present a patient who developed acute pancreatitis after a transperitoneal nephrectomy. A 56-year-old patient was referred to the Department of Urology at the Medical University of Graz for right renal tumor (CT scan verified a 12 cm renal mass) to perform a radical nephrectomy. The preoperative anesthetic screening of our patient showed ASA II according to the American Association of Anesthesiology and well-controlled hypertension with normal laboratory blood tests. There were no co-existing infections.

The histological examination of the right kidney revealed a renal cell carcinoma (RCC).

The operation was uneventful. However, one day later the patient complained of gradually increasing, serious abdominal and back pain, including jaundice and fever.

On physical examination, the patient's abdomen showed guarding and distension. Bowel sounds were hypoactive. The patient had neither a history of biliary lithiasis nor chronic alcohol consumption or infections. Laboratory data (blood) demonstrated urea 61 mg/dl (N: 10-45), uric acid 8.5 mg/dl (N: 3.4-7), potassium 4.3 mmol/l (N: 3.5-5), calcium 1.99 mmol/L (N: 2.20-2.65), aspartate aminotransferase 216 IU/L (N: 0-35), alanine aminotransferase 134 IU/L (N: 0-45), lactate dehydrogenase 404 IU/L (N: 120-240) and amylase 989 IU/L (N: 13-53), lipase 2154 (0-60), and procalcitonin 3.45 (N: 0-0.5). White blood cell count was also raised (13000), as well as CRP 268 mg/l (N: 0-8), bilirubin 1.43 (N: 0.1-1.2 mg/dl),



Figs. 1 and 2. CT Scan with edema of the pancreas as well as intraabdominal fluids.

and creatinine 2.78 mg/dl (0.6–1.3). An abdominal CT scan was performed and demonstrated parenchymal edema of the pancreas (Figs. 1 and 2). Intraabdominal fluid in the perirenal, peripancreatic, and pelvic regions was also observed.

The patient was referred to the intensive care unit and treated conservatively for 15 days – his medical condition improved and he was referred to the department of gastroenterology, where MR cholangiopancreatography showed no biliary stones, and a normal liver. Seven days later our patient was discharged with normal laboratory tests. Follow-up six months after the operation was uneventful.

The International Symposium on Acute Pancreatitis in 1992 defined pancreatic necrosis as the presence of one or more diffuse or focal areas of non-viable pancreatic parenchyma [1]. So, based on the patient's clinical presentation and CT scan findings, the diagnosis of acute pancreatitis [2] as a complication of radical nephrectomy was considered. The patient was referred to the intensive care unit (ICU) and oral intake was prohibited. A nasogastric tube was inserted for decompression and parenteral nutrition was started from a central vein. He also received parenteral antibiotics.

Ten days later, serum pancreatic enzyme levels and white blood cell count returned to normal ranges. Results of an abdominal examination also were normal at this time. Bowel movements became normal, and the patient passed stool. On the same day, the nasogastric tube was removed and restricted oral intake was permitted. On day 16 the patient was discharged from the department of gastroenterology.

DISCUSSION

Transperitoneal radical open nephrectomy is a generally accepted treatment for a renal mass greater than 10 cm in size. In the published literature there are no reports on acute pancreatitis as a complication of renal surgery. The mechanism of pancreatitis is still not known.

According to Burkey [3] retroperitoneal dissection and ischemia could be risk factors for postoperative pancreatitis. However, this was not the case in our patient and trauma to the head of pancreas was avoided.

According to Milian et al [5] the mortality rate of pancreatitis was 8.3% for conservative medical treatment versus 26.5% for surgical treatment.

We used propofol for general anesthesia. Physicians should consider pancreatitis as a potentially life-threatening adverse event associated with propofol [6, 7], which may be due to failure of free fatty acid metabolism secondary to inhibition of free fatty acid entry into the mitochondria.

We hypothesize that propofol could have played a role in the pathophysiology in this condition, because no biliary stone was demonstrated on preoperative or postoperative radiologic studies in the presented case. Additionally, no other predisposing factors (e.g. alcohol, infection, addiction or hypercalcemia as well as history of chronic pancreatitis) for pancreatitis were present in our patient. He had no prior history of abdominal operation.

With this case we wish to highlight the possibility of developing acute pancreatitis following a radical nephrectomy.

REFERENCES

1. Bradley EL III: *A clinically based classification system for acute pancreatitis: summary of the International Symposium on Acute Pancreatitis, Atlanta, GA, September 11 through 13, 1992*. Arch Surg 1993; 128: 586–590.
2. Oruç T, Arda K, Tosun Ö, et al: *The value of computed tomography in the diagnosis of acute necrotising pancreatitis in a renal transplant patient*. HPB (Oxford) 2004; 6: 49–51.
3. Burkey SH, Valentine RJ, Jackson MR, et al: *Acute pancreatitis after abdominal vascular surgery*. J Am Coll Surg 2000; 191: 373–380.
4. Ljunberg B, Cowan N, Hanbury DC, et al: *Guidelines on renal cell carcinoma 2010*. European Association of Urology (EAU) 2010; 58: e29–e38.
5. Milian JW, Portugal SJ, Laynez CHR, et al: *Necrotic acute pancreatitis in the intensive care unit: a comparison between conservative and surgical medical treatment*. Rev Gastroenterol Peru 2010; 30 (3): 195–200.
6. Gottschling S, Larsen R, Meyer S, et al: *Acute pancreatitis induced by short-term propofol administration*. Paediatr Anaesth 2005; 15 (11): 1006–1008.
7. Short TG, Young Y: *Toxicity of intravenous anesthetics*. Best Pract Res Clin Anaesthesiol 2003; 17 (1): 77–89.

Correspondence

Badereddin Mohamad Al-Ali
Medical University of Graz
Department of Urology
7, Auenbruggerplatz 7
A-8036 Graz, Austria
phone: +43 676 761 5811
bader1971@gmx.at