

Extended robotic salvage lymphadenectomy in patients with ‘node-only’ prostate cancer recurrence: initial experience

Konstantin Kolontarev, Alexander Govorov, George Kasyan, Paul Rasner, Alexander Vasiliev, Dmitry Pushkar

Moscow State University of Medicine and Dentistry, Department of Urology, Moscow, Russia

Citation: Kolontarev K, Govorov A, Kasyan G, Rasner P, Vasiliev A, Pushkar D. Extended robotic salvage lymphadenectomy in patients with ‘node-only’ prostate cancer recurrence: initial experience. *Cent European J Urol.* 2018; 71: 162-167.

Article history

Submitted: March 4, 2018

Accepted: May 3, 2018

Published online: June 12, 2018

Corresponding author

Konstantin Kolontarev
Urology Department
of Moscow State
University
of Medicine and Dentistry
127206 Moscow, Russia
21/2, Vucheticha Str.
phone: +7 916 958 82 65
kb80@yandex.ru

Introduction Biochemical relapse (BR) after a primary radical prostatectomy may occur in up to 40 percent of cases. Salvage lymphadenectomy has been proposed in patients with ‘node-only’ driven BR, following a definitive treatment of primary prostate cancer (PCa). We present our initial series of 10 consecutive patients who underwent an extended robotic salvage pelvic lymph node dissection (eRSPLND) for ‘node-only’ recurrent PCa.

Materials and methods It was a prospective study, including patients who presented with biochemical relapse after a primary radical prostatectomy at a median of 3.6 years prior. Clinical work-up that was done, including Magnetic resonance Imaging of chest/abdomen/pelvis and a bone scan, did not reveal any abnormalities. All patients underwent 11Choline PET (Positron Emission Tomography)/CT (Computed Tomography), which identified ‘node-only’ metastases.

Results The median operative time was 73.4 mins, blood loss of 100 cc and hospital stay of 2 days. No patient had intra-operative complications, required an open conversion or any blood transfusion. Clavien II grade complications occurred in 1 patient (10%) and were managed conservatively. On histopathology, the median number of total and positive nodes per patient was 15 and 6, respectively. Overall, in our 10 patients, of the 157 total excised nodes, 38.8% were positive. Overall the median (range) PSA (prostate specific antigen) pre-operatively was 3.5 (1.6–3.7) ng/ml. At 3 months post-operatively, the median (range) PSA was 1.1 (0.2–3.4) ng/ml. This reflects an overall median PSA decrease of 31.4%. In no patient did the post-eRSPLND (extended Robotic Salvage pelvic lymphadenectomy) PSA reach zero.

Conclusions eRSPLND allows the majority of patients to postpone hormonal treatment, which can theoretically decrease the cost of the treatment. 11Choline PET/CT identifies patients who are suitable for the eRSPLND. Longer follow-up is necessary to assess the oncologic outcomes.

Key Words: prostate cancer ↔ recurrence ↔ robotic-assisted lymphadenectomy
↔ multi-parameter magnetic resonance imaging positron-emission tomography

INTRODUCTION

Biochemical relapse (BR) after a primary radical prostatectomy may occur in up to 40 percent of cases [1]. The traditional method of treatment of patients with BR is salvage radiotherapy. In accordance to the European Association of Urology (EAU) Guidelines [2], performance of extended pelvic lymphadenectomy (ePLND) is justified in patients with a high-risk localized prostate cancer and with >5%

risk for metastatic progression. Patients with isolated lymph nodes cancer recurrence have a more favorable prognosis as compared to the patients with prostate cancer with bone or internal organs metastasis [3]. Salvage lymphadenectomy has been proposed in patients with ‘node-only’ driven BR, following a definitive treatment of the primary prostate cancer (PCa). This procedure is typically performed by an open surgery with its associated morbidity. In this paper we present our initial series of 10 con-

secutive patients who underwent an extended robotic salvage pelvic lymph node dissection (eRSPND) for ‘node-only’ recurrent PCa.

MATERIAL AND METHODS

This was a prospective study, which included patients, who presented with a biochemical relapse after a primary radical prostatectomy at a median of 3.6 years prior (Table 1). Clinical work-up, which was done according to the standard protocol prior 11Choline PET/CT (Positron Emission Tomography/Computed Tomography) including MRI (magnetic resonance imaging of chest/abdomen/pelvis) and a bone scan, did not reveal any abnormalities. All patients underwent 11Choline PET/CT, which identified ‘node-only’ metastases along the external iliac lymph nodes (Figure 1), pelvic lymph nodes (Figure 2) and in a group of obturator lymph nodes on both sides (Figure 3).

Patients with other (bony or visceral) metastases were excluded. Risks, complications, alternatives as well as the current data for the salvage ePLND for ‘node-only’ metastatic PCa were discussed. Informed consent was signed in each case.

Robotic technique step-by-step

All procedures were performed by a transperitoneal approach. We did not use ureteral catheters to facilitate the intra-operative identification of the ureters,

as was described by Abreu et al. [4]. Under general anesthesia a 12-mm port for the camera was placed 4 cm above the umbilicus through a midline incision by the Hassan technique. Two 8-mm robotic ports were placed on the right and left pararectal lines, 2 cm above their intersection with the umbilical line. The third 8-mm robotic port was placed 8 cm laterally to the left robotic port. The assistant port (12 mm) was placed about 8 cm laterally to the right robotic port and about 5 cm cranially to the right anterior superior

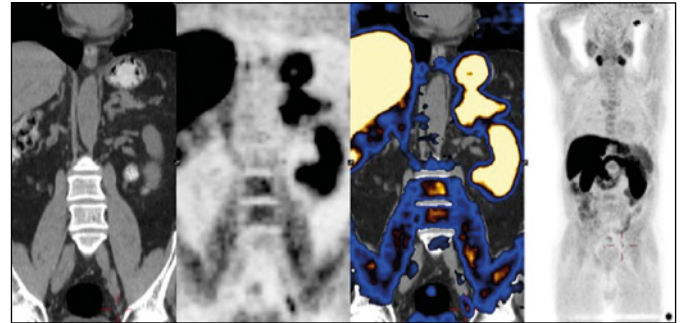


Figure 1. Metastases along the external iliac lymph nodes.

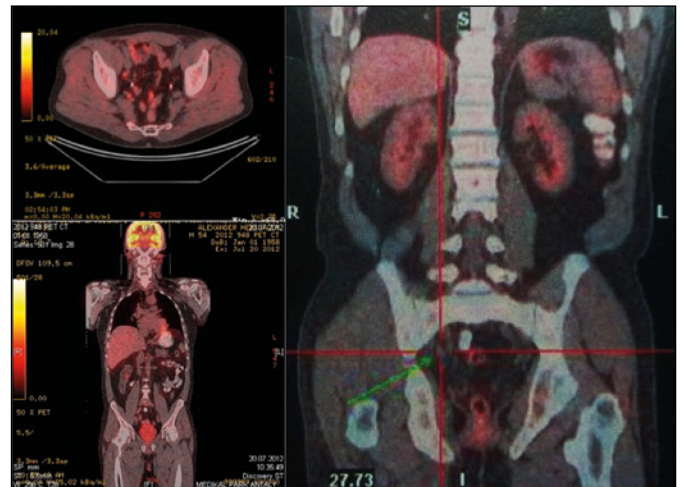


Figure 2. Metastases in pelvic lymph nodes.

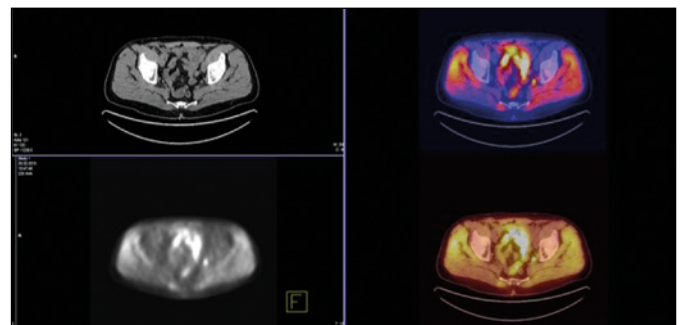


Figure 3. Metastases in a group of obturator lymph nodes on both sides.

Table 1. Baseline demographics

Demographics	Median (range) or N (%)
N	10
Age, years	63 (50–71)
PSA (prostate specific antigen) at initial PCa (primary prostate cancer) diagnosis, ng/ml	8.3 (5.7–13.4)
Primary Gleason score:	
Grade 1	0 (0%)
Grade 2	2 (20%)
Grade 3	5 (50%)
Grade 4	3 (30%)
Grade 5	0 (0%)
TNM (Tumor nodes metastases) stage	
T2cNOMO	8 (80%)
T3aNOMO	2 (20%)
Prior primary treatment:	
Robotic radical prostatectomy (RP)	9 (90%)
Open RP	1 (10%)
Prior PLND (pelvic lymphadenectomy) (at initial RP)	9 (90%)
Number of nodes	7 (6–9)
Time from Primary Treatment, months	44

iliac spine. The patient was placed in deep (35°) Trendelenburg position, the Si HD da Vinci robotic system (Intuitive Surgical, Sunnyvale, CA, USA) was docked. The anatomical limits were: the bifurcation of the common iliac arteries and ureter cranially, the Cloquet's lymph node caudally, the external iliac artery laterally and the bladder wall medially. We used the monopolar scissors, bipolar Maryland forceps and Prograsp. In each case we tried to perform the eRSPLND as close to the ideal technique, described below, as possible, but in most cases the anatomy was changed due to a prior surgery. However, we are describing the step-by-step procedure:

1. The first step is opening the peritoneum by a U incision from left to right, as in the first step of a radical prostatectomy, overlying the common iliac artery and parallel to the external iliac artery until the ureter on both sides. External iliac vessels are identified and exposed.

2. The ureter is identified at its crossing with the common iliac artery, dissected, suspended and then displaced. Once split, the fibro-fatty tissue overlying the distal portion of the common and external iliac vessels, common iliac artery and its bifurcation are visible. The fibro-fatty tissue containing the lymphatics, overlying the internal iliac artery, its medial vesical branches and the presacral lymph nodes are identified and dissected (Figure 4).

3. The external iliac lymph nodes are progressively dissected. Dissection is carried out from the crossing of the ureter over the common iliac artery until the pubic bone at the level of the circumflex vein that is usually preserved and dissected.

4. The obturator fossa is reached and the lymph nodes are progressively dissected until the complete exposure of the obturator nerve. The dissection is started at the angle between the external iliac vein and the pubic bone. The lymphatic package is dissected beneath the external iliac vein, proceeding until the pelvic sidewall, which is the lateral limit of the dissection. The proximal attachments of the lymphatic packages are dissected sharp or blunt, paying attention, in order to avoid any injury to the obturator nerve. The same technique is performed contra-laterally (Figure 5).

5. At the end of the procedure, the anterior peritoneum is sutured by a running 3-0 'barbed' suture. Hemostasis is confirmed and hemostatic agents applied as needed. A drain is placed intra-peritoneally and is usually removed on the 1st postoperative day as well as the Foley catheter.

RESULTS

The median operative time was 73.4 mins, blood loss of a 100 cc and hospital stay of 2 days. No patient

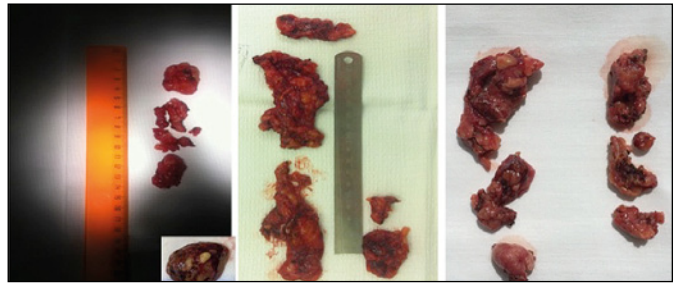


Figure 4. Dissected lymph nodes.

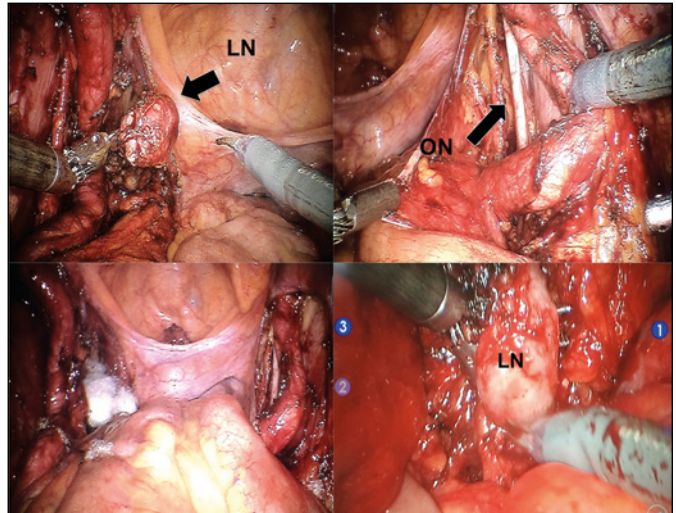


Figure 5. Intraoperative picture.

LN – lymph node; ON – obturator nerve

had intra-operative complications, required an open conversion or any blood transfusion (Table 2). Clavien II grade complications occurred in 1 patient (10%) and were managed conservatively (prolonged antibiotic treatment).

On histopathology, the median number of total and positive nodes per patient was 15 and 6, respectively. Overall, in our 10 patients, of the 157 total excised nodes, 38.8% were positive (Table 3). We found a good correlation between the test results and pathology.

The overall median (range) prostate-specific antigen (PSA) pre-eRSPLND was 3.5 (1.6–3.7) ng/ml. Three months post-operatively; the median (range) PSA was 1.1 (0.2–3.4) ng/ml. This reflects an overall median PSA decrease of 31.4%. In no patient did the post-eRSPLND PSA reach zero. The reason for that could be the presence of other undetectable lymph nodes.

DISCUSSION

The management of patients with recurrent PCa is challenging, 20–40% of patients relapse within

5 years and 25–30% progress to metastatic disease [5]. Ultrasound and computerized imaging methods until recently did not allow to accurately determine the presence and degree of lymphadenopathy. Currently PET/CT is a perspective method of imaging for ‘node-only’ recurrent PCa [2].

The availability of phosphatidylcholine tumor cells in the cell membrane lead to the absorption of the radioactive material 11Choline, which is detected by PET. The sensitivity of 11Choline PET/CT is 38 – 98% [5, 6, 7].

F. Abdollah et al., presented the results of a multicenter study comparing the PET/CT data with the subsequent histological confirmation [1]. The results of the largest-scale studies with the usage of 11C, 18F-Choline and 11C-Acetate are presented in Table 4. The research made, permitted the authors to determine the sensitivity (73–95 percent), specificity (40–93 percent), positive prognosis value (86–92 percent), negative prognosis value (61–87 percent) and singularity (84–90 percent) which proved a high efficiency of this visualization method in the diagnosis of the lymph nodes involvement [8–12]

D. Schilling et al., analyzed the results of 10 patients, who underwent radiotherapy or radical prostatectomy with further laparoscopic dissection of lymph nodes (which were suspicious during PET/CT with 11Choline). In this paper only in 7 cases of PCa were confirmed by histology [13].

J. Winter et al., presented the results of a salvage pelvic lymphadenectomy in 6 patients with ‘node-only’ PCa recurrence on the PET/CT. The average PSA was 2.04 (0.67–4.51) ng/ml. During the histopathological examination of the removed lymph nodes, prostate cancer was verified in all patients [14].

Results of the salvage pelvic lymphadenectomy of 15 patients with PCa recurrence confirmed by PET/CT were presented by L. Rinnab et al. None of the patients had any data regarding the availability of local recurrence or distant metastases. The average level of total PSA was 1.7 ng/ml, average number of removed lymph nodes during the extended pelvic lymphadenectomy -13.9. Median follow-up time was 13.7 months [15].

The possibility of a reliable visualization of the PCa node-only recurrence by 11Choline PET/CT, depends upon several factors, including the PSA level prior to the examination. Thus, according to the opinion of I. de Jong et al., the PET/CT should not be prescribed to patients with PSA level is <5.0 ng/ml because of high false-negative results [6]. However, the subsequent studies that evaluate the usage of PET/CT for patients with PSA level <0.5 ng/ml obtained no data pertaining to the false-negative re-

Table 2. Peri-operative outcomes

Peri-operative outcomes	Median (range) or N(%)
Operative time, mins	73.4
Estimated blood loss, ml	100
Open conversion	0
Blood transfusion	0
Intra-operative complication	0
Drain placed	10
Drain duration, days	1
Hospital Stay, days	2
Complications: Clavien II	1 (10%)

Table 3. Pathological outcomes

Pathological outcomes and follow-up	
No. of nodes excised/patient median (range)	15 (11–18)
No. of positive nodes/patient median (range)	6 (4–9)
Follow-up, days median (range)	165 (131–350)
Post-op PSA, ng/ml median (range)	1.1 (0.2–3.4)
% decrease in PSA	31.4 %
Adjuvant hormonal therapy following eRSPND (extended robotic salvage pelvic lymphadenectomy)	10 (100%)

sults [16]. M. Mamede et al., remarked that besides the PSA level the result of the examination is also influenced by the hormonal treatment [17].

Salvage lymphadenectomy has been performed in over 500 patients reported in 11 publications to date (Table 4). At 8 years, clinical recurrence-free survival and cancer-specific mortality-free survival were 38% and 81%, respectively [18]. Only two papers evaluated laparoscopic/robotic surgery [5, 13]. This series showed comparable results with our study in terms of complication rates and the median number of total and positive lymph nodes per patient [22].

To our knowledge this is one of the largest series of robotic salvage ePLND for ‘node-only’ recurrent PCa. Abreu et al., reported ten cases of robotic salvage RPLND+PLND for positive lymph node recurrent PCa [4]. In this study the mean number of total and positive nodes per patient was 83 (41–132) and 23 (0–109), respectively. Such a large number of removed lymph nodes, was due to much more extended lymph node dissection than in our study. However, authors reported positive nodes on the final histology in 7 out of 10 cases. We found positive

Table 4. Literature review

Author Year	N	Surgery	Patients with +nodes N (%)	Mean nodes (range)	Mean +nodes (range)	PET/CT (Positron emission tomography/Computed Tomography)	Gleason score N (%)	Primary treatment N (%)	Clavien-Dindo complications	Follow-up (months)
Schilling 2008 [13]	10	LAP	7 (70)	7.1 (1–22)	2.8 (0–8)	[11C]Choline	<7 8 (80) >8 2 (20)	RP 8 (80) RT 2 (20)	NA	11
Rinnab 2008 [15]	15	Open	8 (53.3)	13.9 (3–45)	NR	[11C]Choline	<7 11 (73.3) >8 4 (26.7)	RP 15 (100)	NA	
Rigatti 2011 [19]	72	Open	60 (83.3)	30.6 (4–87)	9.08 (0–66)	[11C]Choline	<7 45 (62.4) >8 27 (37.6)	RP 72 (100)	Grade 1 20.8–25% Grade 2 1.4–19.4% Grade 3a 4.1–13.8% Grade 3b 1.4–2.7%	39.4
Jilg 2012 [20]	52	Open	47 (90.4)	23.3 (1–57)	9.74 (0–54)	[11C]Choline [18F] Choline	<7 36 (69) >8 16 (31)	RP 39 (83) RT 8 (17)	Grade 1 1.9–7.7% Grade 2 5.8% Grade 3a 3.9%	40.1
Suardi 2014 [18]	59	Open	47 (79.7)	29.5 (2–87)	8.9 (0–66)	[11C]Choline	<7 38 (64.4) >8 21 (35.6)	RP 59 (100)	Grade 1 20.3–30.5% Grade 2 1.7–20.3% Grade 3a 5.1–11.2% Grade 3b 1.7%	81.1
Tilki 2014 [21]	58	Open	45 (77.6)	18.6 (1–88)	6.3	[11C]Choline	<7 30 (52) >8 28 (48)	RP 58 (100)	NR	39
Jilg 2014 [23]	72	Open	72 (100)	29.5 (2–111)	9.5 (0–81)	[11C]Choline [18F] Choline	<7 34 (47) >8 32 (48)	RP 63 (87.5) RT 8 (12.5)	NR	32
Winter 2015 [24]	13	Open	11 (84.6)	NR	1 (0–3)	[11C]Choline [18F] Choline	<7 8 (61.5) >8 3 (23)	RP 13 (100)	Grade 3b 1 (6.7%)	31
Karnes 2015 [25]	52	Open	52 (100)	23.8 (16–30)	5.3 (1–31)	[11C]Choline	<7 30 (57.7) >8 19 (36.5)	RP 52 (100)	Grade 2 1.9% Grade 3a 1.9% Grade 3b 1.9%	20.9
Clayes 2014 [5]	17	Open LAP RA	15 (88.2)	11.8 (1–21)	2.3 (0–6)	[11C]Choline [18F] Choline	<7 9 (53) >8 8 (47)	RP 14 (82) RT 8 (17) HIFU 1 (6)	Grade 1 35% Grade 2 6% Grade 3a 6–12%	22
Abreu 2016 [4]	10	RA	7 (70%)	83 (41–132)	26 (0–109)	[11C]Acetate	<7 4 (40) >8 6 (60)	RP 8 (80) RT 2 (20)	Grade 1 10% Grade 2 10%	2
Current Study	10	RA	10 (100%)	15 (11–18)	6 (4–9)	[11C]Choline	<7 7 (70) >8 3 (30)	RP 10 (100%)	Grade 2 20%	3

lymph nodes in all ten cases. Moreover, we found a good correlation between the test results and the pathology report.

Clayes et al., reported about 17 cases of salvage lymphadenectomy, but robot-assisted technique was used only in 6 patients. All intraoperative outcomes were comparable to our results (number of removed and positive nodes, complication rate and so on) [5].

We present our technique for performing the eRSPLND. No major intra-operative complications occurred. This is definitely a challenging procedure and should be performed only in specialized centers with great experience of robot-assisted surgery. One of the possible limitations of our study was the use of the 11Choline PET/CT. Prostate-specific membrane antigen (PSMA) PET/CT was not available at that

time. To assess the long-term oncological outcome a larger cohort with longer follow-up period is needed.

CONCLUSIONS

The salvage extended pelvic lymphadenectomy is mostly justified for patients with the PSA level <4 ng/ml, Gleason score ≤7 with ‘node-only’ PCa recurrence. This procedure allows the majority of patients to postpone hormonal treatment, which can theoretically decrease cost of the treatment. Choline PET/CT identifies patients appropriate for the eRSPLND. Longer follow-up is necessary to assess the oncologic outcomes.

CONFLICTS OF INTEREST

The authors declare no conflicts of interest.

References

1. Abdollah F, Briganti A, Montorsi F, et al. Contemporary role of salvage lymphadenectomy in patients with recurrence following radical prostatectomy. *Eur Urol.* 2015; 67: 839-849.
2. Prostate cancer: guidelines. Ads. by Mottet N, Bastian PJ, Bellmunt J, et al. Netherlands: European Association of Urology, 2016; p. 128.
3. Giovacchini G, Picchio M, Gracia-Parra R, et al. 11C-choline PET/CT predicts prostate cancer- specific survival in patients with biochemical failure during androgen deprivation therapy. *J Nucl Med.* 2014; 55: 233-241.
4. Abreu A, Fay C, Park D, et al. Robotic salvage retroperitoneal and pelvic lymph node dissection for 'node-only' recurrent prostate cancer: technique and initial series. *BJU Int.* 2016; 120: 401-408.
5. Claeys T, Van Praet C, Lumen N, et al. Salvage pelvic lymph node dissection in recurrent prostate cancer: surgical and early oncological outcome. *Biomed Res Int.* 2015; 2015: 198543.
6. de Jong IJ, Pruijm P, Elsinga W, et al. C-choline positron emission tomography for the evaluation after treatment of localized prostate cancer. *Eur Urol.* 2003; 44: 32-38.
7. Giovacchini G, Picchio M, Briganti A, et al. 11C-choline positron emission tomography/computerized tomography to restage prostate cancer cases with biochemical failure after radical prostatectomy and no disease evidence on conventional imaging. *J Urol.* 2010; 184: 938-943.
8. Krause BJ, Souvatzoglou M, Tuncel M, et al. The detection rate of 11C-choline-PET/CT depends on the serum PSA-value in patients with biochemical recurrence of prostate cancer. *Eur J Nucl Med Mol Imaging.* 2008; 35: 18-23.
9. Heesakkers RA, Hovels AM, Jager G, et al. MRI with a lymph-node-specific contrast agent as an alternative to CT scan and lymph-node dissection in patients with prostate cancer: a prospective multicohort study. *Lancet Oncol.* 2008; 9: 850-856.
10. Lecouvet FE, El Mouedden J, Collette L, et al. Can whole-body magnetic resonance imaging with diffusion-weighted imaging replace Tc 99m bone scanning and computed tomography for single-step detection of metastases in patients with high-risk prostate cancer? *Eur Urol.* 2012; 62: 68-75.
11. Harisinghani MG, Barentsz J, Hahn PF, et al. Noninvasive detection of clinically occult lymph- node metastases in prostate cancer. *New Engl J Med.* 2003; 348: 2491-2499.
12. Wang L, Hricak H, Kattan MW. Combined endorectal and phased-array MRI in the prediction of pelvic lymph node metastasis in prostate cancer. *AJR Am J Roentgenol.* 2006; 186: 743-748.
13. Schilling D, Schlemmer HP, Wagner PH, et al. Histological verification of 11C-choline-positron emission/computed tomography-positive lymph nodes in patients with biochemical failure after treatment for localized prostate cancer. *BJU Int.* 2008; 102: 446-451.
14. Winter A, Uphoff J, Henke RP, Wawroschek F. First results of 11C-choline PET/CT-guided secondary lymph node surgery in patients with PSA failure and single lymph node recurrence after radical retropubic prostatectomy. *Urol Int.* 2010; 84: 418-423.
15. Rinnab L, Mottaghy FM, Simon J. 11C-Choline PET/CT for targeted salvage lymph node dissection in patients with biochemical recurrence after primary curative therapy for prostate cancer: preliminary results of a prospective study. *Urol Int.* 2008; 81: 191-197.
16. Castellucci P, Fuccio C, Rubello D, et al. Is there a role for 11C-choline PET/CT in the early detection of metastatic disease in surgically treated prostate cancer patients with a mild PSA increase <1.5 ng/mL? *Eur J Nucl Med Mol Imaging.* 2011; 38: 55-63.
17. Mamede M, Ceci F, Castellucci P, et al. The role of 11C-choline PET imaging in the early detection of recurrence in surgically treated prostate cancer patients with very low PSA level <0.5 ng/mL. *Clin Nucl Med.* 2013; 38: e342-345.
18. Suardi N, Gandaglia G, Gallina A, et al. Long-term outcomes of salvage lymph node dissection for clinically recurrent prostate cancer: results of a single-institution series with a minimum follow-up of 5 years. *Eur Urol.* 2015; 67: 299-309.
19. Rigatti P, Suardi N, Briganti A, et al. Pelvic/retroperitoneal salvage lymph node dissection for patients treated with radical prostatectomy with biochemical recurrence and nodal recurrence detected by 11C-choline positron emission tomography/computed tomography. *Eur Urol.* 2011; 60: 935-943.
20. Jilg CA, Rischke HC, Reske SN, et al. Salvage lymph node dissection with adjuvant radiotherapy for nodal recurrence of prostate cancer. *J Urol.* 2012; 188: 2190-2197.
21. Tilki D, Mandel P, Seeliger F, et al. Salvage lymph node dissection for nodal recurrence of prostate cancer after radical prostatectomy. *J Urol.* 2015; 193: 484-490.
22. Coelho RF, Palmer KJ, Moniz RR, et al. Early complication rates in a single-surgeon series of 2500 robotic-assisted radical prostatectomies: report applying a standardized grading system. *Eur Urol.* 2010; 57: 945-952.
23. Jilg CA, Schultze-Seemann W, Drendel V, et al. Detection of lymph node metastasis in patients with nodal prostate cancer relapse using (18)F/(11)C-choline positron emission tomography/computerized tomography. *J Urol.* 2014; 192: 103-110.
24. Winter A, Henke RP, Wawroschek F. Targeted salvage lymphadenectomy in patients treated with radical prostatectomy with biochemical recurrence: complete biochemical response without adjuvant therapy in patients with low volume lymph node recurrence over a long-term follow-up. *BMC Urol.* 2015; 15: 10.
25. Karnes RJ, Murphy CR, Bergstralh EJ, et al. Salvage lymph node dissection for prostate cancer nodal recurrence detected by 11C-choline positron emission tomography/computerized tomography. *J Urol.* 2015; 193: 111-116. ■