

# Necessity of routine histopathological evaluation subsequent to bladder neck contracture resection

Mehmet Kaynar<sup>1</sup>, Murat Gul<sup>2</sup>, Mustafa Kucur<sup>3</sup>, Esin Çelik<sup>4</sup>, M. Serdar Bugday<sup>2</sup>, Serdar Goktas<sup>1</sup>

<sup>1</sup>Selcuk University School of Medicine, Department of Urology, Konya, Turkey

<sup>2</sup>Van Training and Research Hospital, Van, Turkey

<sup>3</sup>Batman State Hospital, Batman, Turkey

<sup>4</sup>Selcuk University School of Medicine, Department of Pathology, Van, Turkey

**Citation:** Kaynar M, Gul M, Kucur M, Çelik E, Bugday S, Goktas S. Necessity of routine histopathologic evaluation subsequent to bladder neck contracture resection. Cent European J Urol. 2016; 69: 353-357.

## Article history

Submitted: June 18, 2016

Accepted: Oct. 15, 2016

Published online: Nov. 30, 2016

## Corresponding author

Murat Gul

Van Training and Research Hospital

Department of Urology

65000 Van, Turkey

phone: 905056316913

drgulacademics@gmail.com

**Introduction** Bladder neck contracture is a well-known complication following some urologic surgical procedures. Regardless of the surgical procedure, any specimen resected should be submitted for histopathological evaluation worldwide. However, the charges of histopathological evaluation may bring a heavy burden to the hospital and health care system. Also, waiting the period of the pathological evaluation process can be an anxious time for patients. Hence, we aimed to investigate the necessity of routine histopathological evaluation of bladder neck contracture bladder neck contraction specimens.

**Material and methods** Patients undergoing bladder neck contraction resection, from 2010 to 2015 were identified. Patient demographics, type of surgery and histopathological diagnosis and cost of histopathological analyses of the specimens were recorded and analyzed.

**Results** Findings of the histopathologic evaluations of 340 bladder neck specimens were reviewed. Out of these, 294 had underwent transurethral resection of the prostate, 38 open prostatectomy, and 8 radical prostatectomy. Evidence of malignant disease involving prostate cancer was present in only 2 specimens. Both of the specimens had a known preexisting history of malignant disease. The remaining 338 specimens showed chronic inflammation (n = 176), chronic active inflammation (n = 64), adenomatous hyperplasia (n = 78) or cystitis (n = 20).

**Conclusions** Our results indicate that routine histopathological examination of bladder neck contraction specimens is clinically unnecessary. We recommend that the surgeon should decide the need for histological examination on individual basis, depending on known preoperative risk factors.

**Key Words:** bladder neck contracture <> fibrosis <> routine histopathology

## INTRODUCTION

Bladder neck contracture (BNC) is a complication witnessed after surgical procedures for the treatment of non-neurogenic male lower urinary tract symptoms (LUTS), localized prostate cancer (PCa), transurethral resection of prostate (TURP), and radical prostatectomy (RP) with an incidence between 1.4 and 4.7% [1, 2]. Common BNC management options are cold-knife, electrocautery, laser, and loop resection [3–7]. The specimen that is resected is submitted for histopathological evaluation. However,

the histopathological result does not change the course of subsequent management since BNC formation involves progression from inflammation to fibrosis [8, 9]. Moreover, recurrent histopathological evaluation will be necessary as the BNC recurs [10, 11]. Hence, frequent histopathological BNC specimen evaluation leads to a financial burden to the health care system and to additional, mostly unnecessary, patient anxiety until the results are announced [12]. The effectiveness of recurrent histopathological evaluations for diagnostic purposes is unclear as there are, according to our best knowledge,

no relevant studies. The aim of the present study is to understand and clarify the necessity of routine histopathological evaluation of BNC specimens.

## MATERIAL AND METHODS

Following the approval of the local ethics committee, data of 352 patients who underwent TUR either with Gyrus™ Plasma Kinetic (PK) tissue management system (Gyrus Medical Ltd, Bucks, UK) thin Super loop for resection at settings of 160 W cutting and 80 W coagulation or ESG-400 SurgMaster TUR in saline (TURis®) (Olympus, Tokyo, Japan) from January 2010 to January 2015 were evaluated retrospectively. There were only two centres involved in the present study. These were selected according to convenience sampling method.

Inclusion criteria were patients with lower urinary tract symptoms due to BNC and indications for surgical treatment. BNC diagnosis was confirmed using flexible cystoscopy and participants were categorized as Group 1, consisting of patients without PCa but developed BNC after TURP or open prostatectomy and as Group 2, diagnosed with PCa who underwent RP or TURP and developed subsequently BNC. Patient demographics, type of surgery and histopathological diagnosis of the specimens were collected from the patients' medical records. Information about the cost of BNC macroscopic and microscopic analyses were obtained from the relevant departments of the participating centres. Whereas patients with PCa of all stages were included, and the presence of Bladder carcinoma (BCa) was the single exclusion criteria. SPSS 22.0 (SPSS Inc., Chicago, IL, USA) was employed for statistical analyses.

## RESULTS

Out of the 352 patients studied initially, 340 were considered as eligible. Out of these, 294 had underwent TURP, 38 open prostatectomy, and 8 RP. The histological evaluations revealed that 176 patients had chronic inflammation (51.7%), 78 adenomatous hyperplasia (22.9%), 64 chronic active inflammation (18.8%), and 20 cystitis (0.5%). Only 2 patients (0.05%) revealed PCa. Both of them were in Group 2 and their Gleason's score was 3+3 and 3+4. Table 1 and 2 shows demographic features, time of contraction, histopathological diagnosis distribution, and operation types.

## DISCUSSION

BNC, a common postoperative TURP and RP complication, is of recurrent nature and has a substan-

tial impact on quality of life as well as on the health-care system. Transurethral incision or resection of the contracture are common endoscopic treatment modalities [13]. Subsequent to BNC resection, specimens obtained are sent for histopathological evaluation as a necessity determined by the treatment protocol. However, this procedure does not only create a serious, yet mostly unnecessary, anxiety for the patients, but also to massive financial burden for health care systems and increased workload for pathologists. Therefore, today the need for routine histopathological evaluations is being questioned more and more. In their review, Younis et al. aimed to evaluate the utility and cost effectiveness of obtaining histopathological diagnosis in all routine tonsillectomy specimens and found no unexpected pathologies in 2099 cases [14]. There are also several studies in line with the findings of previous studies

**Table 1.** Demographic features of patients with BNC

	Group 1 (n = 307; 90.2%)	Group 2 (n = 33; 9.7%)	P Value*
Age (y)	65.04 ±6.72	69.82 ±4.97	.000
Time of contraction (d) (after primary operation)	185.79 ±95.54	124.7 ±75.56	.015
Prostat volume (cc)	42.76 ±25.55	45.24 ±26.05	.598

\*Student t test

**Table 2.** Histopathological diagnosis distribution and operation types of patients with BNC

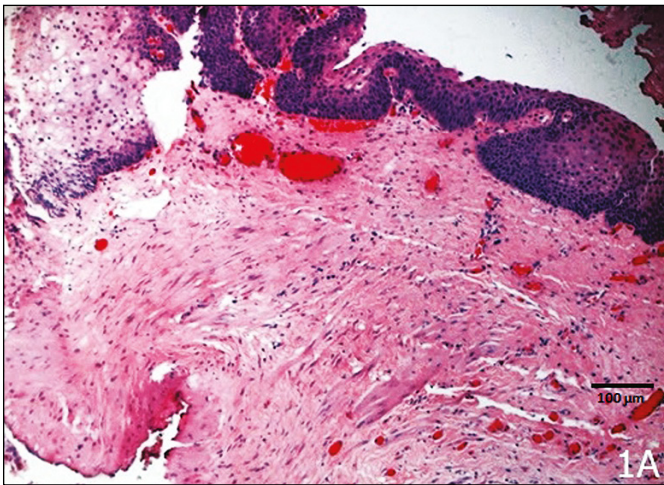
	Group 1 (n = 307; 90.2%)	Group 2 (n = 33; 9.7%)	Total
Operation Type			
TURP	271 (88.3%)	23 (69.7%)	294
Open prostatectomy	36 (11.7%)	2 ( 6.1%)	38
Radical prostatectomy	0 (0 %)	8 (24.2%)	8
Histopathologic diagnosis			
Chronic inflammation	161 (47.3%)	15 (4.4%)	176
Active chronic inflammation	51 (15%)	13 (3.8%)	64
Adenomatous hyperplasia	76 (22.3%)	2 (0.5%)	78
Cystitis	19 (5%)	1 (0.29%)	20
Prostate adenocancer	0 (0%)	2 (0.5%)	2

stating that routine histopathological examination is unnecessary for tonsillectomy [15, 16, 17]. In another study, routine histopathological examination of septal tissue following surgery for obstruction is not only unnecessary but also not cost-effective [18]. Moreover, some authors have already discussed and recommended a selective approach for the histopathological evaluation of gallbladders [19, 20, 21]. In a prospective study, Yeh et al. suggest a more selective approach for the histopathological evaluation of nasal polyp specimens [22]. Another study questioned routine histological evaluation of pediatric hernial sac and claimed it to be unnecessary [23]. Likewise, Bernardini et al. questioned the necessity of histopathological evaluation of the lacrimal sac during dacryocystorhinostomy and recommended

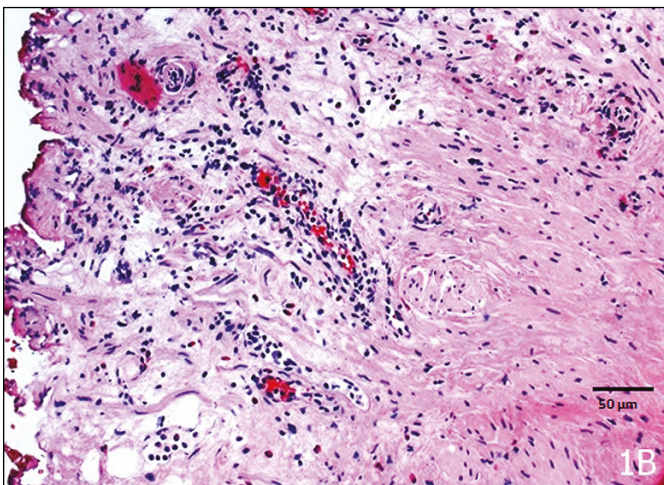
that lacrimal sac biopsy should be performed only in those with known risk factors [24]. Moreover, Clark and Bauer outlined that routine histological evaluation of uncomplicated osteoarthritis specimens may not be necessary [25]. A common feature of all of the above mentioned studies is the main reason for surgery is not suspected malignancy, but a functional disorder (obstruction etc.). They all claim that the cost of histopathological evaluation of surgical specimens is high and do not recommend it in the absence of malignancy risk factors. The present study is, according to our best knowledge, the first evaluating the necessity of routine histopathological examination of BNC specimen. Moreover, recurring BNC requires another intervention and thus another histopathological evaluation. In the present retrospective study, only two patients had positive histopathological evidence for malignancy and previous PCa history. The first patient had PCa diagnosis with a Gleason's score of 3+3, and of T1b stage after TURP; and the other had radiation induced BNC for PCa of Gleason 3+4 and of stage T1c. However, histopathological results did not alter the clinical course of treatment for both patients with a known history of malignancy. On the other hand, in persisting PSA cases after radical surgery without metastases on imaging but with a positive histology, TURP patients should be considered for radiotherapy after counselling.

The exact mechanisms of BNC is still unclear. Excessive resection of the bladder neck, robust fulguration at the bladder neck, and hypertrophic scarring produced by a large resection loop generating extensive heat during TUR are amongst the suggested predisposing factors [26, 27]. On the other hand, the proposed factors contributing to BNC development following RP consist of urinary extravasation, extensive blood loss, prior radiation, and patient characteristics (smoking status, age, BMI, hypertension, diabetes mellitus etc.) [28]. RP is thought to generate progressive obliterated endarteritis which eventually predisposes to necrosis and fibrosis of the bladder neck [8]. Whatever the mechanism, inflammation and fibrosis are the most important factors leading to BNC. Hence, the histopathological analysis of 338 specimens (99.5%) showed varying degrees of inflammation, fibrosis, or benign conditions (Figure 1A and 1B), whereas only two specimens (0.05%) showed malignant histopathology.

Microscopic evaluation of adenoidectomy was reported by Alvi and Vartanian as costing \$25 per patient [29]. Younis et al. reported in 2001 that Medicare allowed \$4.82 for gross evaluation and \$12.85 for microscopy [14]. In the present study, the histopathological analysis for each patient would be



**Figure 1A.** Mild fibrosis and congested blood vessels are seen beneath the surface epithelium of the prostatic urethra (HE x100).



**Figure 1B.** Chronic inflammatory cells predominantly including lymphocytes within the fibromuscular stroma (HE x200).

around \$20. Hence, the total cost for the Turkish healthcare system of the cases included was \$6760. \$6720 were spent in vain, as only two cases revealed PCa, which were already known. For the remaining 336 cases, it was only an unnecessary psychological burden as the pathological analyses took 2–3 weeks to be concluded.

Malignant formation at the bladder neck is generally driven by BCa or PCa. BCa may occur or recur anywhere in the bladder including the bladder neck. BCa patients were excluded from the present study as the stage may shift and thus, the treatment change subsequent to BNC surgery. However, PCa course and treatment would not be affected by the histopathological results of the BNC specimen obtained during surgery. Therefore, BCa presence was the single exclusion criteria.

The inherent limitations of the present study are that it is retrospective and nonrandomized. A prospective setting with follow up changes in the decision of the urologist with the histological analysis results could shed a better light on the situation.

## CONCLUSIONS

Health care system policies necessitate routine histopathological examination of all surgically-resected specimens. The major reason for the present study

was to show that the result of histopathological examinations of BNC specimens does not influence the clinical course of management. Results indicate that in the absence of previous risk factors (T3 or T4 stage PCa or bladder tumor), routine histological evaluation of bladder neck specimens is not necessary. To do otherwise, will result in increased burden on the healthcare system and on pathologists. However, to decrease the burden on the healthcare system and patients, legal aspects of not sending the tissue to the pathologist after surgery are to be considered. Depending on the regulations and the laws of each country, taking the written consent of the patients may be sufficient. Further prospective studies with larger samples are needed to confirm our findings.

## CONFLICT OF INTEREST

The authors declare no conflicts of interest.

## ETHICAL APPROVAL

All procedures performed in studies involving human participants were in accordance with the ethical standards of the institutional and/or national research committee and with the 1964 Helsinki declaration and its later amendments or comparable ethical standards.

## INFORMED CONSENT

Informed consent was obtained from all individual participants included in the study.

## References

- Madersbacher S, Marberger M. Is transurethral resection of the prostate still justified? *BJU Int.* 1999; 83: 227-237.
- Parihar JS, Ha YS, Kim IY. Bladder neck contracture—incidence and management following contemporary robot assisted radical prostatectomy technique. *Prostate Int.* 2014; 2: 12-18.
- Anger JT, Raj GV, Delvecchio FC, et al. Anastomotic contracture and incontinence after radical prostatectomy: a graded approach to management. *J Urol.* 2005; 173: 1143-1146.
- Yurkanin JP, Dalkin BL, Cui H. Evaluation of cold knife urethrotomy for the treatment of anastomotic stricture after radical retropubic prostatectomy. *J Urol.* 2001; 165: 1545-1548.
- Pansadoro V, Emiliozzi P. Iatrogenic prostatic urethral strictures: classification and endoscopic treatment. *Urology.* 1999; 53: 784-789.
- Surya BV, Provet J, Johanson KE, et al. Anastomotic strictures following radical prostatectomy: risk factors and management. *J Urol.* 1990; 143: 755-758.
- Brede C, Angermeier K, Wood H. Continence Outcomes After Treatment of Recalcitrant Postprostatectomy Bladder Neck Contracture and Review of the Literature. *Urology.* 2014; 83: 648-652.
- Kovell RC, Terlecki RP. Management Strategies for Post-Prostatectomy Bladder Neck Contractures. *Curr Urol Rep.* 2015; 16: 65.
- Metcalfe PD, Wang J, Jiao H, et al. Bladder outlet obstruction: progression from inflammation to fibrosis. *BJU Int.* 2010; 106: 1686-1694.
- Brodak M, Kosina J, Pacovsky J, et al. Bipolar transurethral resection of anastomotic strictures after radical prostatectomy. *J Endourol.* 2011; 24: 1477-1481.
- Giannarini G, Manassero F, Mogorovich A, et al. Cold-knife incision of anastomotic strictures after radical retropubic prostatectomy with bladder neck preservation: efficacy and impact on urinary continence status. *Eur Urol.* 2008; 54: 647-656.
- Walshe K, Smith J. Comprehensive spending review and the NHS. *BMJ.* 2015; 351: h6477
- Ramirez D, Simhan J, Hudak SJ, et al. Standardized approach for the treatment of refractory bladder neck contractures. *Urol Clin North Am.* 2013; 40: 371-380.
- Younis R, Hesse S, Anand V. Evaluation of the utility and cost effectiveness of obtaining histopathologic diagnosis on all routine tonsillectomy specimens. *Laryngoscope.* 2001; 111: 2166-2169.
- Erdag TK, Ecevit MC, Guneri EA, et al. Pathologic evaluation of routine tonsillectomy and adenoidectomy

- specimens in the pediatric population: is it really necessary? *Int J Pediatr Otorhinolaryngol.* 2005; 69: 1321-1325.
16. Randall DA, Martin PJ, Thompson LDR. Routine histologic examination is unnecessary for tonsillectomy or adenoidectomy. *Laryngoscope.* 2007; 117: 1600-1604.
  17. Nelson ME, Gernon TJ, Taylor JC, et al. Pathologic evaluation of routine paediatric tonsillectomy specimens analysis of cost effectiveness. *Otolaryngol Head Neck Surg.* 2011; 144: 778-783.
  18. Haffey T, Pabon S, Hawley K, et al. Exploring the clinical value and implications of routine pathological examination of septoplasty specimens. *Laryngoscope.* 2012; 122: 2373-2377.
  19. Siddiqui FG, Memon AA, Abro AH, et al. Routine histopathology of gallbladder after elective cholecystectomy for gallstones: waste of resources or a justified act? *BMC.* 2013; 13: 1471-1482.
  20. Dix FP, Bruce IA, Krypczyk A, et al. A selective approach to histopathology of the gallbladder is justifiable. *Surgeon.* 2003; 1: 233-235.
  21. Mittal R, Jesudason MR, Nayak S. Selective histopathology in cholecystectomy for gallstone disease. *Indian J Gastroenterol.* 2010; 29: 26-30.
  22. Yeh DH, Wong J, Hoffbauer S, et al. The utility of routine polyp histopathology after endoscopic sinus surgery. *Int Forum Allergy Rhinol.* 2014; 4: 926-930.
  23. Siddiqui K, Nazir Z, Ali SS, et al. Is routine histological evaluation of pediatric hernial sac necessary? *Pediatr Surg Int.* 2004; 20: 133-135.
  24. Bernardini FP, Moin M, Kersten RC, et al. Routine histopathologic evaluation of the lacrimal sac during dacryocystorhinostomy: how useful is it? *Ophthalmology.* 2002; 109: 1214-1217.
  25. Clark CR, Bauer T. Routine pathological examination of operative specimens from primary total hip and total knee replacement: another look. *J Bone Joint Surg Am.* 2000; 82: 1529-1530.
  26. Robinson HP, Greene LF. Postoperative contracture of the vesical neck. II. Experimental production of contractures in dogs: transurethral series. *J Urol.* 1962; 87: 610-616.
  27. Jonas U, Petri E, Hohenfellner R. Indication and value of bladder neck incision. *Urol Int.* 1979; 34: 260-266.
  28. Herschorn S, Elliott S, Coburn M, et al. SIU/ICUD consultation on urethral strictures: posterior urethral stenosis after treatment of prostate cancer. *Urology.* 2014; 83: S59-70.
  29. Alvi A, Vartanian A. Microscopic examination of routine tonsillectomy specimens: is it necessary? *Otolaryngol Head Neck Surg.* 1998; 119: 361-363. ■



Sponsor of the award for  
**the best scientific paper published in  
 Central European Journal of Urology**